



Comparative Efficacy of 50% Trichloroacetic Acid Solution with 10% Potassium Hydroxide Solution in the Treatment of Plane Warts

Reza Yaghoobi¹, Nader Pazyar¹ and Bahareh Maleki^{1,2*}

¹Department of Dermatology, Ahvaz Jundishapur University of Medical Sciences, Ahvaz, Iran.

²Department of Dermatology, Imam Hospital, Ahvaz, Iran.

Authors' contributions

This work was carried out in collaboration among all authors. Authors RY and NP designed the study, performed the statistical analysis and wrote the protocol. Author BM managed the analyses of the study, wrote the first draft of the manuscript and managed the literature searches. All authors read and approved the final manuscript.

Article Information

DOI: 10.9734/JPRI/2019/v27i430178

Editor(s):

(1) Dr. Barkat Ali Khan, Department of Pharmaceutics, Gomal University, Dera Ismail Khan, Pakistan.

Reviewers:

(1) Shruti Ghadgepatil, Dr. DY Patil Medical College, India.

(2) Mehwish Zafar, Jinnah Medical & Dental College, Pakistan.

(3) Muhammad Wasif Saleem, Ziauddin University, Karachi, Pakistan.

Complete Peer review History: <http://www.sdiarticle3.com/review-history/44864>

Received 30 September 2018

Accepted 10 December 2018

Published 17 May 2019

Original Research Article

ABSTRACT

Background: Warts are very common disorders. Plane warts are caused by Human Papilloma Virus (HPV) occurring mostly in children and young adults. Among the treatment modalities, topical application of trichloroacetic acid (TCA) is age old. Potassium hydroxide (KOH) has a keratolytic effect on virus-infected cells.

Aims: To compare the safety and efficacy of topical 10% KOH solution with 50% TCA solution in the treatment of plane warts.

Materials and Methods: Sixty-four consecutive patients with plane warts were randomly assigned into two groups of thirty-two patients. Group A received 10% KOH solution and group B received 50% TCA solution once weekly until the complete clearance of warts in a maximum period of 12 weeks.

Results: In group under treatment with 10% KOH, 24 patients (75.0%) complete response, 5 patients (15.6%) moderate response, 2 patients (6.3%) mild response, and 1 patient (3.1%) had no

*Corresponding author: E-mail: bahareh.maleki@iran.ir;

response. In group under treatment with 50% TCA, 28 patients (87.5%) showed complete response, 2 patients (6.3%) moderate response, 2 patients (6.3%) mild response. Statistically no significant difference was found between the therapeutic response to 10% KOH and 50% TCA (P=0.41).

Conclusion: 10% KOH was found to be equally effective in the treatment of plane warts compared to 50% TCA with the advantage of fewer side effects.

Keywords: Plane warts; potassium hydroxide; trichloroacetic acid; therapy.

1. INTRODUCTION

Warts are caused by infection of keratinocytes by human papillomavirus (HPV). The incidence increases during childhood to reach a peak in adolescence and early adulthood then declines rapidly through the 20s and more gradually thereafter [1]. Its prevalence among children has reported to be between 2-20% in different communities [2]. Verruca plana or plane warts are caused by HPV types 3, 10, 28, and 41, occurring mostly in children and young adults. Sites of predilection are face, back of hands, and the shins. They are 2-4 mm flat-topped papules and are erythematous or brown-colored on pale skin and hypopigmented on darker skin [3]. They have the tendency to koebnerize, especially in the children [3].

Diagnosis and treatment of the disease is very important in terms of beauty issues and preventing the proliferation of warts [4]. Today, many different treatments are used to eliminate warts, which include two major groups of medical treatments and surgical procedures [5]. Medical treatments due to the need for continuous use, and skin sensitivities and side effects are not widely popular among patients [4,5]. In addition, surgical treatments have reduced efficacy due to complications such as scars and the possibility of recurrence of warts [4,5]. There are many modalities for the treatment of plane warts that includes topical salicylic acid, glycolic acid, 5-fluorouracil, isotretinoin gel, topical zinc sulfate solution, citric acid, trichloroacetic acid (TCA), bacillus Calmette-Guérin immunotherapy, curettage/electrodessication, and cryotherapy [6-10]. Most treatments focus primarily on the destruction or removal of visible lesions or on the induction of cytotoxicity against the infected cell. Among these agents, TCA and potassium hydroxide (KOH) are less stimulant and cause less scar [11,12].

TCA is a topical destructive agent and causes hydrolysis of cellular proteins leading to cell death. It is effective in treating common, cervical,

genital, and anal warts in the concentrations of 70-80% and has response rates comparable to cryotherapy [11,12]. Low concentrations (10-30%) are used for the treatment of common warts and superficial peeling. The advantage is the complete lack of systemic toxicity; however, a few local effects such as pain, burning, hyperpigmentation, and rarely scar formation may occur [13].

Potassium hydroxide is a strong metallic base used in the diagnosis of fungal infections, Whiff test for bacterial vaginosis, treatment of male genital warts, and the treatment of molluscum contagiosum in children [14-17]. It acts by its keratolytic effects that lead to the destruction of virus-infected cells causing resolution of warts. Potassium hydroxide is less irritating, less painful, less scar forming, and can be safely used in children too. Rarely, side effects such as itching, erythema, and dyspigmentation may be seen. KOH holds better promise for the treatment of warts according to a few studies [18]. Hence, it was felt worthwhile exploring this agent for the treatment of plane warts.

The aim of this study was to compare the efficacy and safety of topical 10% KOH with 50% TCA in the treatment of plane warts.

2. MATERIALS AND METHODS

A randomized, controlled trial was conducted at the Department of Dermatology, Ahvaz Imam Hospital, Southwest Iran, during August 2017 to February 2018. A total of 64 patients with age more than 4 years and plane warts ranging from 3 to 30 in number were included in the study. Pregnant and nursing women, patients with hypersensitivity to KOH or TCA, patients currently using any treatment for warts within the last 1 month, patients with comorbid conditions such as diabetes mellitus or immunosuppression were excluded from the study. Patients are divided into 2 groups A (10% KOH) and B (50% TCA). Each groups contains thirty-two patients and matched with respect to the age and sex. A

four random permutation method was chosen to select the patients for both groups. Informed consent form was taken and ethical clearance obtained from the University Ethical Committee (IR.AJUMS.REC.1396.703). The diagnosis of plane warts was made clinically with special attention to the morphology of lesions and loss of skin markings over the lesions. Location, size, and number of warts were recorded.

Group A received topical 10% KOH solution and group B received topical 50% TCA solution once weekly by the physician. In both groups, a cotton-tipped toothpick dipped in the solution was applied once to the wart under Vaseline cover of surrounding skin, keeping it perpendicular to the skin surface. The patients were observed for 15 min for any side effects. The therapy was continued until the completion of 12 weeks or till all the lesions cleared, whichever was earlier. Both the groups were examined at the end of 4 weeks, 8 weeks, and 12 weeks to evaluate the response to treatment and for any side effects.

Clinical resolution of the warts was determined by objective responses. Patients, physician and those who measured the results did not know how to place patients in the groups, as well as the drugs were prepared similarly in terms of appearance (packaging, color and odor).

On follow ups, number and size of the warts were measured to use for classification of results.

Based on physician's perception of overall percentage of resolution of warts, patients were classified as complete responders: Complete disappearance (100%) of all the warts both in size and number, partial responders who were in turn classified as moderate responders: More than 50% (51-99.9%) reduction in number of warts, mild responders: <50% (1-50%) reduction in number of the warts and non responders: No reduction in the number.

Data analysis was performed using SPSS version 24. Mean and standard deviation for quantitative variables and absolute and relative frequencies for qualitative variables were determined. The therapeutic efficacy level in the two groups was compared with the chi-square test and the significance level was 0.05.

3. RESULTS

A total of 64 patients (32 in each group) were finally assessed at 12 weeks. Twenty-nine

(45.3%) patients were males and 35 (54.7%) were females. Age of the patients ranged from 4 years to 51 years, duration of warts from a week to 5 years, number of warts varied from 3 to 30, and size of smallest wart ranged between 1 and 2 mm. The wart location and demographic variables of each group have been collected in Table 1. Both the groups were comparable with respect to different independent variables including sex, age, number, size, and duration of lesions ($P > 0.05$). No patient had any comorbidities or any state of immunosuppression.

Study results at 12 weeks showed that in KOH group, 24 patients (75.0%) had complete response, 5 patients (15.6%) moderate response, 2 patients (6.3%) mild response, and 1 patient (3.1%) had no response. In TCA group B, 28 patients (87.5%) showed complete response, 2 patients (6.3%) moderate response, 2 patients (6.3%) mild response. Statistically no significant difference was found between the therapeutic response to 10% KOH and 50% TCA ($P=0.41$) [Table 2, Fig. 4]. However, it was noticed that the percentage of patients showing complete clearance (100% response) was more in TCA group which was 87.5% as compared to 75% in KOH group but no statistical significance was found. On analysis, the average percentage reduction in number of warts in two groups showed no statistically significant results ($P = 0.41$) [Tables 1,2].

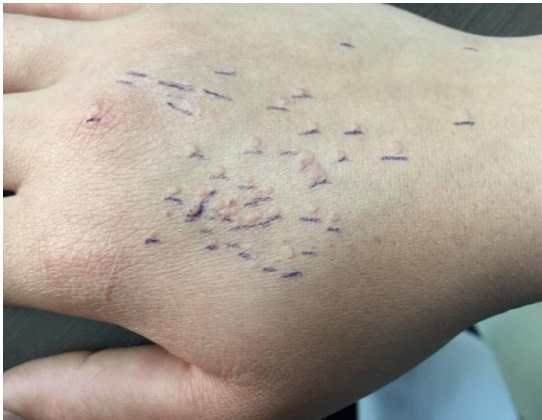On comparison of the response in the two groups based on the site of warts, size of warts, sex of patients, age of patients, and duration of disease no statistical difference was observed ($P > 0.05$). Other information such as time to improve, logistic regression and treatment efficacy have been mentioned in Tables 3, 4 and Figs. 3, 4, 5 and 6.

Burning sensation occurred in 25 patients (78.1%) in KOH group immediately after consumption for a transient period of less than one minute and in 32 patients (100%) in TCA group for a transient time of 1- 2 minutes. Erythema was seen in all patients (100%) in TCA group during the procedure which disappeared within 10-15 min. Crust was also seen in 10 patients (31.2%) in KOH group and in all patients in TCA group at the place of consumption. Dyspigmentation was seen in 14 patients (43.7%) in KOH group (hypo-hyperpigmentation) and in all patients (100%) in TCA group which was completely resolved during follow-up, except

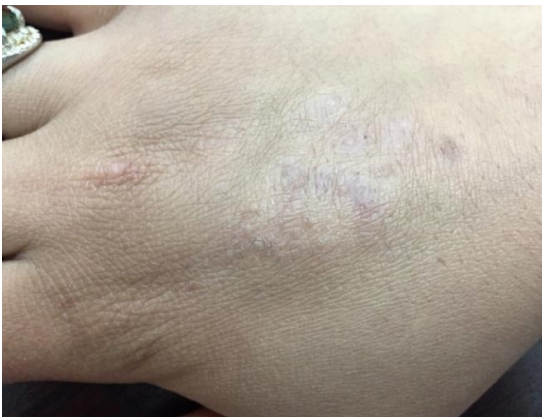for 2 cases of hyperpigmentation, both of which were children and hyperpigmentation was still evident one month after discontinuation of treatment, but had color reduction. On follow-up of the patients with complete response after 2 months, two patients had recurrence of warts in TCA group.

agents which are safer, inexpensive, and easy to use in case of plane warts. This study compared the efficacy of such two well-known agents, 10% KOH, and 50% TCA in the treatment of plane warts. It was noticed that the average percentage reduction in wart number at the end of 12th week, show no difference.

In one of the most recent studies, by examining the solution of KOH 5% and the tretinoin lotion 0.1% in 72 patients with plane warts for 6 weeks, Yaghoobi et al. [20] showed that 59.8% in the KOH group and 64.1% in the tretinoin group decreased lesions. Side effects in the KOH group were slightly higher than the tretinoin group. In our present study, the efficacy of both drugs was higher than that of Yaghoobi et al. [20], while there was no significant difference between the two groups like their study.



Before treatment with 50%TCA

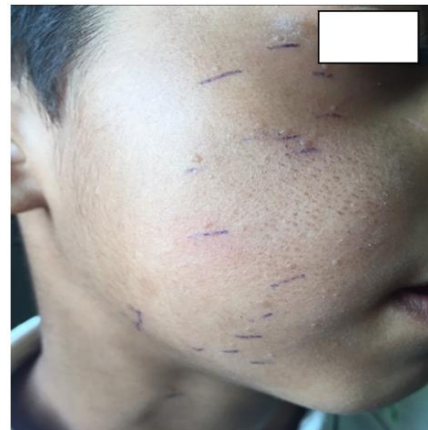

After treatment (12th week)

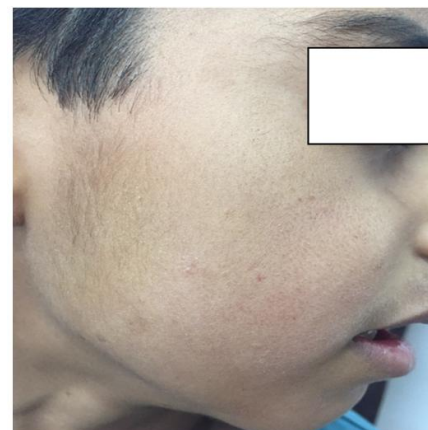Fig. 1.

4. DISCUSSION

A multitude of therapies is available for the treatment of common warts with varying degrees of success ranging from the age-old destructive treatment to cryotherapy and the newly emerging therapies such as pulsed dye laser, intralesional immunotherapy, and autoinoculation therapy [9,11,19]. However, studies on plane warts are scarce. There are insufficient data available to show the efficacy and strength of recommendation for topical destructive or caustic



Before treatment with 10% KOH



After treatment (8th week)

Fig. 2.

Table 1. General characteristics of the patients in group A & B

Variables	Group A	Group B	Total	p-value
Age (years)	19.25±12.27	25.70±15.54	22.42±14.23	0.07
Gender	Male (46.9%) 15	(46.9%) 15	30 (46.9%)	0.69
	Female (53.1%) 17	(53.1%) 17	34 (53.1)	
Disease time (months)	16.50±18.19	7.32±8.77	11.91±14.9	0.01
Warts number	10.92±8.44	12.75±10.20	11.87±9.35	0.46
Minimum size (mm)	1.0±0.00	1.03±0.17	1.01±0.12	0.32
Maximum size (mm)	2.59±1.62	2.43±1.56	2.51±1.58	0.69
Anterior Location	Head and Neck (65.3%) 21	(56.3%) 18	39 (60.9)	0.62
	Trunk (3.1%) 1	0 (0.0%)	1 (1.6)	
	Limbs (12.5%) 4	2 (6.3)	6 (9.4)	
	Head and Neck & Limbs (3.1%) 1	3 (9.4)	4 (6.3)	
Posterior Location	Head and Neck (3.1%) 1	0	1 (1.6)	0.54
	Trunk (3.1%) 1	0	1 (1.6)	
	Limbs (21.9%) 7	(37.5%) 12	19 (29.7)	

Table 2. Efficacy of treatment in two groups

Time	Efficacy	Group A		Group B		P-value
		N	%	N	%	
Week 4	Complete response	14	43.8%	14	43.8%	0.46
	No response	1	3.1%	0	0.0%	
	Response less than 50%	12	37.5%	9	28.1%	
	Response more than 50%	5	15.6%	9	28.1%	
Week 8	Complete response	23	71.9%	24	75.0%	0.79
	No response	1	3.1%	0	0.0%	
	Response less than 50%	2	6.3%	2	6.3%	
	Response more than 50%	6	18.8%	6	18.8%	
Week 12	Complete response	24	75.0%	28	87.5%	0.41
	No response	1	3.1%	0	0.0%	
	Response less than 50%	2	6.3%	2	6.3%	
	Response more than 50%	5	15.6%	2	6.3%	
Total	Complete response	24	75.0%	28	87.5%	0.41
	No response	1	3.1%	0	0.0%	
	Response less than 50%	2	6.3%	2	6.3%	
	Response more than 50%	5	15.6%	2	6.3%	

Table 3. Time to improve

p-value	Index (time to improve/week)					Groups
	Std.	Mean	Max	Min	N	
0.73	3.75	6.37	12.00	2.00	32	A
	3.18	5.81	12.00	2.00	32	B
	3.46	6.09	12.00	2.00	64	Total

Table 4. Logistic regression to examine the relationship between different factors and improvement

	%95 CL		(OR)	P	df	Wald	S.E.	B	Variable
	Upper	Lower							
10.660	.328	1.870	.481	1	.497	.888	.626	Gender	
1.205	.974	1.083	.141	1	2.172	.054	.080	Age	
1.016	.923	.968	.190	1	1.719	.025	-.032	Duration of infection	
2.188	.620	1.165	.635	1	.225	.322	.153	Largest dimensions	
2.188	.620	1.165	.635	1	.225	.322	.153	Smallest dimensions	
1.009	.906	.956	.100	1	2.709	.027	-.045	Number	
13.405	.352	2.171	.404	1	.696	.929	.775	Medication	

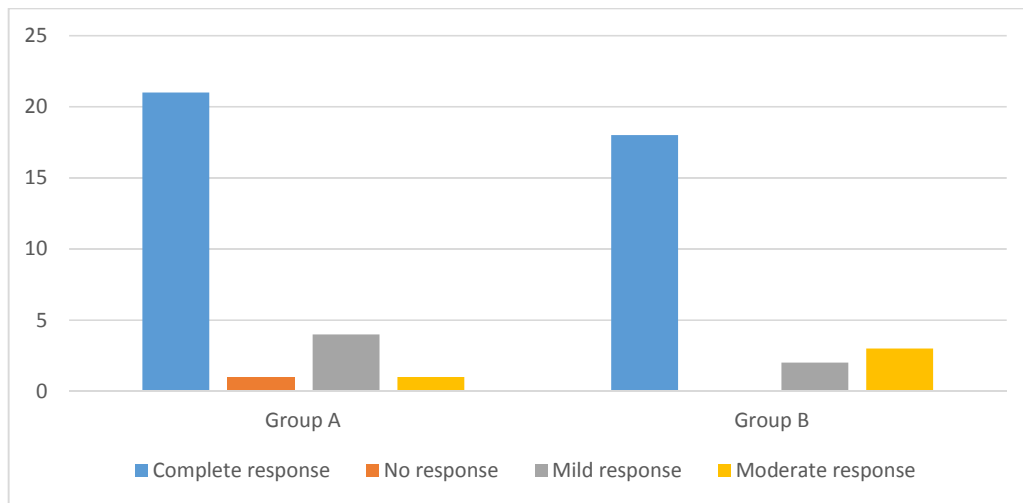


Fig. 3. Treatment efficacy

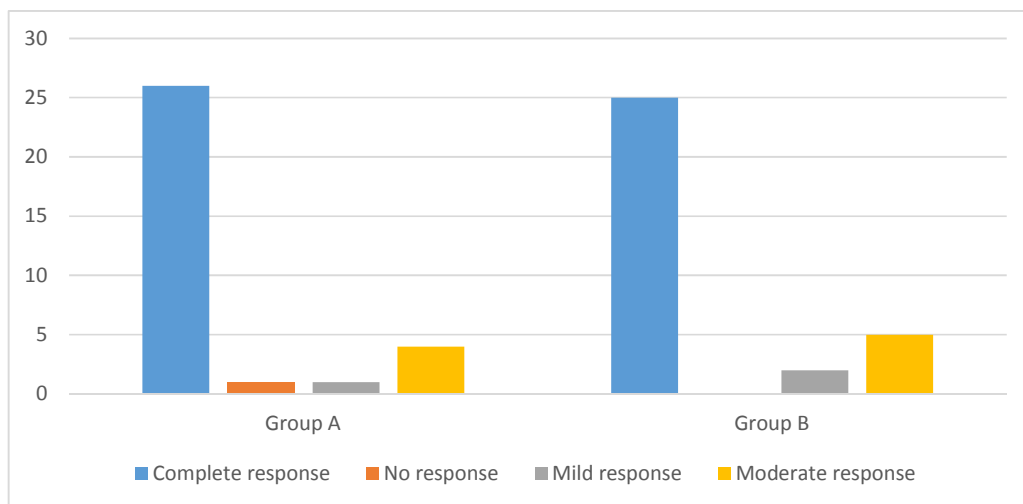


Fig. 4. Treatment efficacy-week 12th

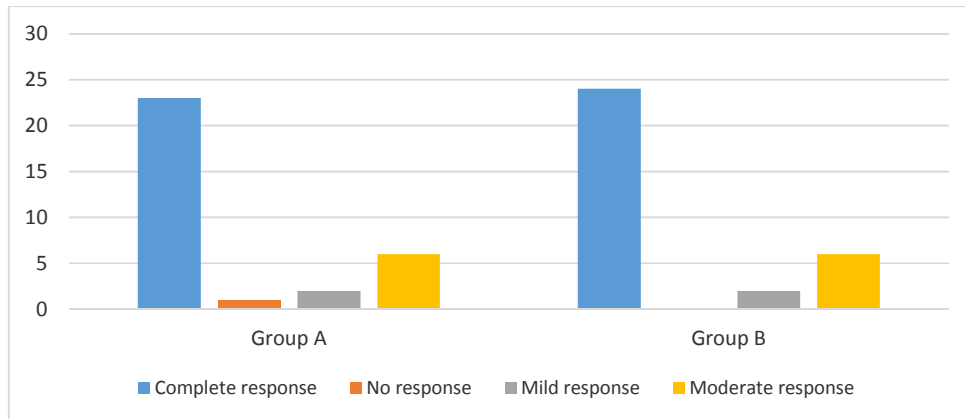


Fig. 5. Treatment efficacy-week 8th

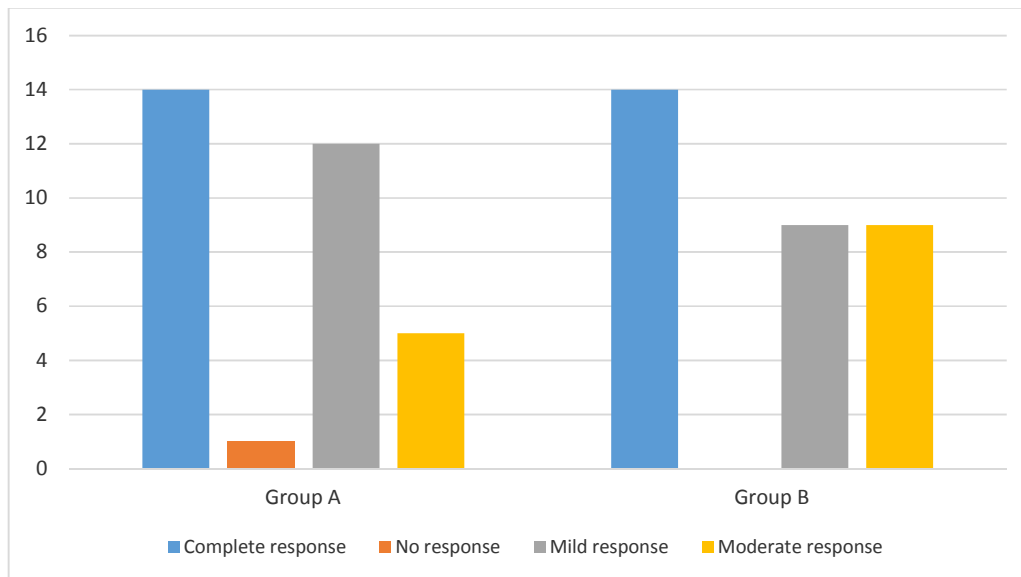


Fig. 6. Treatment efficacy-week 4th

Al-Hamdi and Al-Rahmani [18] compared the effects of 5% and 10% KOH on plane warts with once daily application for 4 weeks. Patients under treatment with 5% KOH showed 80.3% complete response in comparison with 82.1% of 10% KOH group. Nearly 14.7% showed partial response and 3.15% showed no response in 10% KOH group. The difference in the cure rate for patients showing complete disappearance was not significant at the end of therapy. However, 5% KOH solution showed a slower action in comparison with 10% KOH solution. In addition, the recurrence rates of warts among patients showing complete response were 5.8% in 5% KOH group versus 5.1% in 10% KOH group. All the warts in the study by Al-Hamdi and Al-Rahmani were located on the face. This study

has closer efficacy to the current study, and it can express more general findings in the effective use of these drugs.

In another single-blinded clinical trial by Pezeshkpoor et al. [12] 62 patients with common warts were randomly divided into two groups and were applied 80% TCA or 35% TCA once per week until complete clearance of the lesions for a maximum duration of 6 weeks. Results showed good response rate 46.7% in group 80% and good response rate 12% in group 35%, which was significant in improvement between the two treatment groups. Improvement was greater with a higher concentration of TCA solution (80%). The results showed that 35% TCA had a lower clearance rate seen at the end of 6 weeks (12%)

which is almost similar to our study (11.11%) at the end of 12 weeks. It can be interpreted that more time is probably needed for TCA to show complete response or higher concentration (>35%) can be tried. The present study showed more efficacies compared to the study of Pezeshkpoor and examined the wider variables. Review of literature shows that TCA in higher concentration (60-80%) has equal cure rates in genital warts compared to cryotherapy [11]. The British Association of Dermatologists guidelines suggest 50-80% TCA weekly application for 8 weeks for treating hand warts [21].

A study by Taner et al. [22] treated 51 women with genital warts with TCA 85%, showed a good response to TCA with high efficacy and low morbidity. Although the type of warts was different in their study and, the effective use of the referred drug was mentioned with a common goal, such as the present study.

In another study by Jayaprasad et al. [23] by examining 60 patients with plane warts treated by 30% TCA or 10% KOH, the therapeutic efficacy of KOH was better at the end of 4 and 8 weeks but at the end of 12 weeks, there was no difference between two groups. The main difference between their study and the present study was the difference in the efficacy of the drugs at the end of 4 and 8 weeks. The follow-up of patients was also more in that study that could also examine differences of both groups in the long term, whereas this is not the case in this study.

Also, the use of non-pharmacological methods along with KOH has also shown that this drug is effective and competitive and comparable with other methods for the improvement of patients, including Asadi et al. in [24] in Iran divided 70 patients with warts into two groups of CO₂ and KOH laser recipients, which the results showed that 88.9% in both groups were fully cured and the efficacy of the two methods was statistically similar.

Similarly, in the study of Cengiz et al. [25], patients with plane warts were divided into three groups: cryotherapy, TCA 10% and TCA 25% that the response to treatment was similar in three groups, and finally 10% TCA was introduced as a more convenient and safe method.

Finally, in the study of Layegh et al. [26] 60 women with genital warts received 80% TCA or

cryotherapy. The response to treatment in the TCA group was 96.5% and in the cryotherapy group was 93.1%. Relatively, TCA had a faster efficacy in the treatment process.

Overall findings indicate that KOH and TCA could be used as safe and effective choices, not only in comparison with other drugs, but also in comparison with other therapeutic methods.

5. CONCLUSION

This study showed that use of 10% KOH solution and 50% trichloroacetic solution in patients with plane warts could effectively improved plane warts. Both the agents are less expensive, easy to apply, and well suited for the self-treatment of plane warts by the patients. Hyperpigmentation seen with 50% TCA may make it less promising in the treatment of plane warts over the face in young females. Also, 10% KOH can be considered as an effective, safe, cosmetically acceptable, and first line therapy for plane warts in immune competent individuals.

6. LIMITATIONS OF THE STUDY

The sample size was not enough to compare the results of drugs efficacy in generalized population. Small population size led to small sample size, which is due to limited number of medical centers.

7. RECOMMENDATION

We recommend bigger cohorts to have more accurate results. Agents could have been used twice weekly rather than once weekly for better results. Future studies are recommended to evaluate more variables with larger samples size and wider medical centers. More control group can be considered along with the case group or non-therapeutic methods can be used in comparison with the case group.

CONSENT AND ETHICAL APPROVAL

Informed consent form was taken and ethical clearance obtained from the University Ethical Committee (IR.AJUMS.REC.1396.703).

COMPETING INTERESTS

Authors have declared that no competing interests exist.

REFERENCES

1. Sterling JC. Virus infections. In: Burns T, Breatnach S, Cox N, Griffith C, Editors. *Rook's Textbook of Dermatology*. 8th Ed. West Sussex, UK: Wiley-Blackwell. 2004;3339-41.
2. Kilkenny M, Marks R. The descriptive epidemiology of warts in the community. *Australas J Dermatol*. 1996;37(2):80-6.
3. Hunter JA, Savin JA, Dahl MV. *Clinical dermatology*. 4th Ed. New Jersey: Blackwell Publishing Company. 2008;235-9.
4. Berth-Jones J, Hutchinson PE. Modern treatment of warts: Cure rates at 3 and 6 months. *Br J Dermatol*. 1992;127(3):262-5.
5. Goldfarb MT, Gupta AK, Gupta MA, Sawchuk WS. Office therapy for human papillomavirus infection in nongenital sites. *Dermatol Clin*. 1991;9(2):287-96.
6. Vali A, Ferdowsi F. Evaluation of the efficacy of 50% citric acid solution in plane wart treatment. *Indian J Dermatol*. 2007;52:96-8.
7. Salih HR, Fadeel BM. Evaluation of isotretinoin gel and oral zinc sulphate in the treatment of plane warts. *J Fac Med Baghdad*. 2008;50:4.
8. Sharquie KE, Khorsheed AA, Al-Nuaimy AA. Topical zinc sulphate solution for treatment of viral warts. *Saudi Med J*. 2007;28:1418-21.
9. Sharquie KE, Al-Rawi JR, Al-Nuaimy AA, Radhy SH. BacilleCalmette-Guerin immunotherapy of viral warts. *Saudi Med J*. 2008;29:589-93.
10. Borbujo J, Olmos O, Zamora E, Diez JJ. Treatment of verrucae plana with 15% glycolic acid. *Int J Dermatol*. 2000;39:236-7.
11. Godley MJ, Bradbeer CS, Gellan M, Thin RN. Cryotherapy compared with trichloroacetic acid in treating genital warts. *Genitourin Med*. 1987;63:390-2.
12. Pezeshkpoor F, Banihashemi M, Yazdanpanah MJ, Yousefzadeh H, Sharghi M, Hoseinzadeh H. Comparative study of topical 80% trichloroacetic acid with 35% trichloroacetic acid in the treatment of the common wart. *J Drugs Dermatol*. 2012;11:e66-9.
13. Soliman MM, Ramadan SA, Bassiouny DA, Abdelmalek M. Combined trichloroacetic acid peel and topical ascorbic acid versus trichloroacetic acid peel alone in the treatment of melasma: A comparative study. *J Cosmet Dermatol*. 2007;6:89-94.
14. Brodell RT, Helms SE, Snelson ME. Office dermatologic testing: The KOH preparation. *Am Fam Physician*. 1991;43:2061-5.
15. Metkar A, Pande S, Khopkar U. An open, nonrandomized, comparative study of imiquimod 5% cream versus 10% potassium hydroxide solution in the treatment of molluscum contagiosum. *Indian J Dermatol Venereol Leprol*. 2008;74:614-8.
16. Loureiro WR, Cação FM, Belda W, Jr, Fagundes LJ, Romiti R. Treatment of genital warts in men with potassium hydroxide. *Br J Dermatol*. 2008;158:180-1.
17. Camargo CL, Belda Junior W, Fagundes LJ, Romiti R. A prospective, open, comparative study of 5% potassium hydroxide solution versus cryotherapy in the treatment of genital warts in men. *An Bras Dermatol*. 2014;89:236-40.
18. Al-Hamdi KI, Al-Rahmani MA. Evaluation of topical potassium hydroxide solution for treatment of plane warts. *Indian J Dermatol*. 2012;57:38-41.
19. Lal NR, Sil A, Gayen T, Bandyopadhyay D, Das NK. Safety and effectiveness of autoinoculation therapy in cutaneous warts: A double-blind, randomized, placebo- controlled study. *Indian J Dermatol Venereol Leprol*. 2014;80:515-20.
20. Yaghoobi R, Tajalli M, Mapar M, Pazyar N. Comparative study of 5% potassium hydroxide solution vs. 0.1% tretinoin lotion in the treatment of plane warts: A randomized controlled trial. *Int J Pharmacy and Technology*. 2016;8:11442-11450.
21. Sterling JC, Handfield-Jones S, Hudson PM. British Association of Dermatologists. Guidelines for the management of cutaneous warts. *Br J Dermatol*. 2001;144:4-11.
22. Taner ZM, Taskiran C, Onan AM, GURSOY R, Himmetoglu O. Therapeutic value of trichloroacetic acid in the treatment of isolated genital warts on the external female genitalia. *J Reprod Med*. 2007;52(6):521-5.
23. Jayaprasad S, Subramanian R, Devgan S. Comparative evaluation of topical 10% potassium hydroxide and 30% trichloroacetic acid in the treatment of plane warts. *Indian J Dermatol*. 2016;61(6):634-9.

24. Asadi N, Hemmati E, Namazi G, Jahromi MP, Sarraf Z, Pazyar N, et al. A comparative study of potassium hydroxide versus CO2 laser vaporization in the treatment of female genital warts: A controlled clinical trial. *Int J Community Based Nurs Midwifery*. 2016;4(3):274-82.
25. Cengiz FP, Emiroglu N. An open, comparative clinical study on the efficacy and safety of 10% trichloroacetic acid, 25% trichloroacetic acid and cryotherapy for verruca plana. *Cutan Ocul Toxicol*. 2015;34(2):144-8.
26. Layegh P, Pezeshkpour FAZ, Shakeri MT, Mousavi S. Comparison of the efficacy of 80% trichloroacetic acid with cryotherapy using liquid nitrogen in the treatment of anogenital warts. *IR J Dermatology*. 2007;10:174-180.

© 2019 Yaghoobi et al.; This is an Open Access article distributed under the terms of the Creative Commons Attribution License (<http://creativecommons.org/licenses/by/4.0>), which permits unrestricted use, distribution, and reproduction in any medium, provided the original work is properly cited.

Peer-review history:
The peer review history for this paper can be accessed here:
<http://www.sdiarticle3.com/review-history/44864>