



A Veil of Superstition Unveiled – An Exotic Manifestation of Susuk

**Uday Kumar Umesan^{1*}, Noryagandi Abu Bakar², Sarah Sani¹
and Priya Balakrishnan³**

¹*Universiti Brunei Darussalam, Jalan Tungku Link Gadong, Bandar Seri Begawan, Brunei Darussalam BE1410, Brunei.*

²*National Dental Centre, Old Airport Road, Berakas, Bandar Seri Begawan, Brunei Darussalam BB3513, Brunei.*

³*Private Practice, No.17, Simpang 41-39, Kampong Kiarong, Bandar Seri Begawan, Brunei Darussalam BE1318, Brunei.*

Authors' contributions

This work was carried out in collaboration among all authors. Author UKU was involved in conceptual design of manuscript, analysis, drafting the work, critical review and revision of intellectual content and final approval of version to be published. Author NAB played a role in acquisition and editing of work, critical revision of intellectual content and final approval of version to be published. Author SS was involved in acquisition and editing of work, critical revision of intellectual content and final approval of version to be published. Author PB was involved in design of the manuscript, drafting the work, critical review and revision of intellectual content and final approval of version to be published. Together, we certify that we have each made a substantial contribution to the manuscript so as to qualify for authorship and that we have individually approved the contents.

Article Information

Editor(s):

(1) Dr. Roberta Gasparro, University of Naples Federico II, Italy.

Reviewers:

(1) Damla Torul, Ordu University, Turkey.

(2) Nilton Rodrigues Alves Peres Domingues, Universidade de Santo Amaro, Brazil.

Complete Peer review History: <http://www.sdiarticle4.com/review-history/59325>

Case Study

Received 10 May 2020

Accepted 16 July 2020

Published 30 July 2020

ABSTRACT

The occurrence of radio-opaque embedded foreign entities on dental radiographs, especially after dental treatment or maxillofacial trauma is not uncommon. Alongside such commonplace radiopacities, there is the occasional report of disparate artifacts being observed as incidental findings on dental pantomographs. One such entity is Susuk, or charm needles that are implanted subcutaneously in the facial region and elsewhere in the body. While this phenomenon has been reported primarily from the South-east Asian region; increasing international travel in the modern

*Corresponding author: Email: udayku71@yahoo.com, uday.umesan@moh.gov.bn;

age could render these radiopaque entities a diagnostic challenge for the unacquainted clinician. In a deviation from the classically reported needle-type susuks, this paper reports a case involving insertion of multiple, springy type, filamentous, strands in the orofacial region; manifesting on the pantomograph as a meshed- veil that has never been reported in the literature.

Keywords: Foreign bodies; incidental findings; radiography; dental; radiography; panoramic; needles.

1. INTRODUCTION

The occurrence of embedded foreign entities on dental radiographs is not uncommon. Barring the incidence of commonplace radiopacities like iatrogenic restorative material remnants, broken instruments, embedded foreign bodies following traumatic injuries or even patient adornments; there is the occasional report of extraneous radio-opaque bodies observed as incidental findings on dental radiographs [1]. Among the latter, the most frequently observed radiopacities have been ascribed to charm needles or 'Susuk' (as they are acknowledged colloquially). Much has been written about this mystical practice that traces its origins to people in the South-east Asian region [2]. They are a form of talisman inserted subcutaneously, mostly in the face and less frequently in other parts of the body, but are not visible externally [3–8]. The belief is that these implants will enhance or preserve the wearer's beauty, youth, charisma, strength or health, or even to bring success in business [3,9].

The usually reported types in the literature comprise small, often needle-like structures of varying lengths that are implanted subcutaneously primarily in the facial region [10]. The numbers of needles inserted in an individual have been reported to vary in number from a single one to as many as 80 needles [2,6].

We report an unusual case of susuk that was diagnosed incidentally on dental radiographs in a patient seeking routine dental treatment. In contrast to the traditionally observed needle-like linear inserts, this case curiously involved insertion of multiple, springy type, filamentous strands subcutaneously in the orofacial region. Radiographically, they manifested as a tangled, meshed veil-like web, which to the best of our knowledge, has never been reported previously in the dental literature.

2. PRESENTATION OF CASE

56-year old Chinese female reported to the National Dental Centre, Brunei, with a 1-week

history of dull aching pain on the lower left side of the jaw. She was healthy with an unremarkable medical history. The patient's history was negative for previous trauma or surgery in the maxillofacial region under general anesthesia. She had no associated fever, swelling or lymphadenopathy. Clinical oral exam revealed a tender lower left permanent first molar (36), that was previously root canal obturated more than two years ago. A complete fracture of the lingual wall on 36 was detected at the sub-gingival level. Oral hygiene was deemed to be fair. Routine orthopantomogram (OPG) (refer Fig. 1) demonstrated a heavily restored dentition with moderate loss of alveolar bone support and peri-apical radiolucency associated with an underfilled root-canal treated 36 confirming the diagnosis of chronic apical periodontitis possibly due to failed root canal treatment. Curiously, the OPG also showed multiple, long and filamentous, springy radio-opacities of varying lengths, criss-crossing haphazardly, observed bilaterally in the region of the mandibular rami and posterior teeth giving the appearance of a diffuse and tangled, meshed veil-like web in posterior aspects of the oral cavity.

Intra-oral peri-apical radiograph of 36 (Fig. 2), confirmed an underfilled distal root and a fractured tip of a root canal instrument in the distal canal. Supplementary findings observed included multiple thread-like springy radio-opaque filaments having the appearance of strewn party streamers.

After confirming that there were no foreign objects in the digital capture and processing sensors of the digital radiography machine that could be attributed to the presentation; the findings were discussed with the patient. After much persuasion, she reluctantly admitted that she had gold susuks placed in her face a year ago in order to improve her facial aesthetics and enhance her social appeal. Further, as these implants were not evident on palpation and the patient having no other associated discomfort; it was decided that no additional investigations were necessary based on the principle of

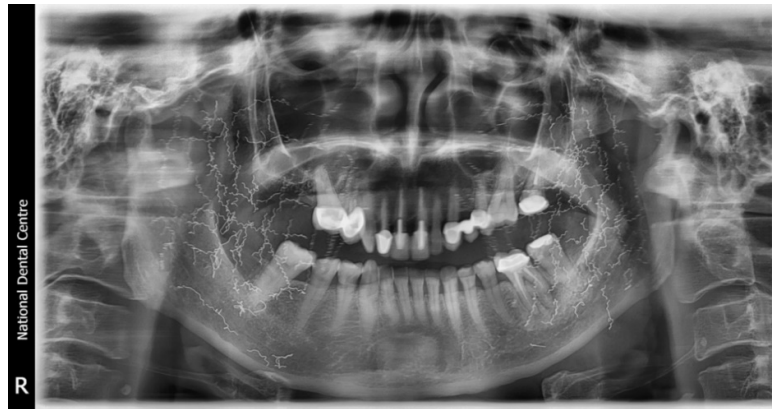

Fig. 1. Panoramic radiograph showing multiple, filamentous, springy radio-opacities of varying lengths, criss-crossing haphazardly; observed bilaterally in the region of the mandibular rami and posterior teeth

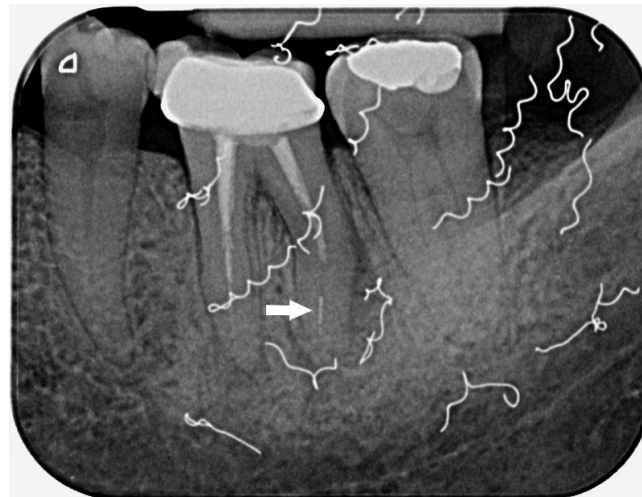


Fig. 2. Peri-apical radiograph of tooth 36 showing thread-like springy radio-opaque filaments having the appearance of strewn party streamers. The short filling and the fractured instrument tip in the distal root can also be seen (white arrow)

'primum non-nocere' (first, do no harm). Therefore, only her primary complaint was addressed and resolved by extraction of 36 owing to its poor restorability with the provision of replacement by an implant at a later date.

3. DISCUSSION

A search of the published literature was carried out using Pubmed and Google Scholar in order to retrieve previous publications on susuk. The outcome has been collated in Table 1.

This exercise confirmed that there was no prior report of a similar shaped-susuk being encountered during dental radiography. Our

patient reluctantly disclosed that she had sought the services of a native traditional healer for placement of these metallic inserts. She could not recall having had any discomfort or pain during or after the procedure. She also claimed that strict instructions were given by the practitioner to be complied with in order to maintain the potency of the charm; the nature of which she refused to divulge for fear of failure of the charm.

Although the precise historical origins of this ancient practice of 'susuk' are still uncertain; this practice is deeply rooted in superstitious beliefs and dates back to the pre-Islamization era in South-east Asia. Similar practices have been

reported in other Asian cultures but are quite unrelated, like the Japanese 'hari' and Chinese 'acupuncture'. While these are placed to therapeutically relieve various medical ailments; susuks are embedded in the belief that these inserts could enhance the appeal, beauty, confidence and charm of the wearer. This may be primarily why they are more commonly identified in the maxillofacial region of older women [11]. A fair proportion of patients observed with susuks also believe that these inserts could cure them of chronic ailments like headache, pain in the joints, back or abdomen [4].

Scientific analyses of charm needles revealed that they are comprised of inert materials like pure gold, silver or alloys of noble metals or sometimes even diamonds [12]. This may explain why charm needles are very biocompatible and tend to remain hidden for many years until they are discovered incidentally on radiographs. The needles vary between 0.5 to 1 mm in diameter and 5 to 10mm in length and, are inserted subcutaneously by witch craftsmen or traditional healers called 'bomoh' (Malay shaman) [13]. The procedure of insertion itself is reportedly accompanied by incantations and invocations while gently rubbing the skin such that it is reported painless and leaves no puncture marks or blood. After

insertion, the needles are painless, not visible to the eye and are not easily felt on palpation [14].

In clinical practice, susuks may be confused with foreign bodies that could be erroneously reasoned to be the source of the patients' symptoms based on the site of their insertion particularly in the oro-faciomaxillary region. Although most susuk wearers tend to be secretive about their hidden talismans, these needles are being discovered with increasing frequency now that radiographs are used routinely. Furthermore, the presence of susuk may interfere with the quality of dental radiographs and or Computed Tomography. Balasundram et al. [15] reported that ultrasound imaging done to detect the needle in their patient to facilitate surgical removal was disrupted by a reflective echo. Instances may arise when a single charm needle over a particular location of jaws is present and clinicians who are not familiar with the existence of such talisman may be confused by this foreign body, and unnecessary investigative procedures and treatment may be prescribed. Such a presence may mimic root canal fillings, restorative pins or fractured instruments thus causing the surgeon to attempt removing them. The literature however, does not report any study on the long-term effects of these inserts.

Table 1. Search results showing retrieved publications on Susuk detailing type of inserts and region of insertion

Year	Author(s)	Type of Susuk	Region of insertion
2020	Garg et al.	Linear pin / needle	Oro-facial
2020	Rampal et al.	Linear pin / needle	Face, lower back, chest wall
2019	Martin & Vlachou	Linear pin / needle	Wrists, knees
2017	Jurkiewicz et al.	Linear pin / needle	Face, breast, hips, legs
2017	Kanneppady et al.	Linear pin / needle	Oro-facial
2017	Varghese et al.	Linear pin / needle	Oro-facial
2016	Divakar et al.	Linear pin / needle	Oro-facial
2016	Hussin et al.	Linear pin / needle	Tibia, feet
2014	F & Mohammed	Linear pin / needle	Oro-facial
2013	Sharif et al.	Linear pin / needle	Oro-facial
2013	Balasundram et al.	Linear pin / needle	Oro-facial
2012	Passi & Sharma*	Staple pin	Dental
2012	Pothiawala	Linear density	Pelvis, left abdomen
2011	Pande	Linear pin / needle	Lower back, knees
2008	Nambiar et al.	Linear pin / needle	Cranio-facial
2007	Tandjung	Linear pin / needle	Oro-facial
2006	Nor et al.	Linear pin / needle	Oro-facial
2006	Teo	Linear pin / needle	Oro-facial
1991	Shanmuhasuntharam & Ghani	Linear pin / needle	Oro-facial

* This report was on unusual foreign bodies in the oro-facial region

4. CONCLUSION

This case describes a previously unreported type of susuk, in contrast to the traditional needle-type charm inserts that have almost always been reported as incidental findings on dental radiographs. An awareness of this practice and its' variations are important to avoid misdiagnosis and subsequent mismanagement of such patients. With increasing cross border travel, dental practitioners in other geographical regions need to be aware of such foreign bodies, as they may at times pose a baffling diagnostic challenge given that these radiological oddities bear close resemblance to incomplete root fillings, amalgam pins or posts.

CONSENT

All authors declare that 'written informed consent was obtained from the patient (or other approved parties) for publication of this case report and accompanying images.

ETHICAL APPROVAL

As per international standard or university standard written ethical approval has been collected and preserved by the author(s).

COMPETING INTERESTS

Authors have declared that no competing interests exist.

REFERENCES

1. Omezli MM, Torul D, Sivrikaya EC. The prevalence of foreign bodies in jaw bones on panoramic radiography. *Indian J Dent.* 2015;6(4):185–9.
2. Nambiar P, Ibrahim N, Tandjung YRM, Shanmuhasuntharam P. Susuks (charm needles) in the craniofacial region. *Oral Radiol.* 2008;24(1):10.
3. Rampal S, Tan EK, Gendeh HS, Prahasthiji LJ, Zainal S, Amir S. The precarious use of charm needles susuk in treatment of low back pain by traditional medicine practitioners and its possible risk to patient safety. *Med J Malaysia.* 2020; 75(1):80–2.
4. Pande K. Incidental findings of Susuk in Orthopaedic patient. *Brunei Int Med J.* 2011;7:177–80.
5. Hussin P, Mawardi M, Lim KK. Susuk: Mysterious incidental finding. *Turk J Emerg Med.* 2016;16(1):45–6.
6. Nor MM, Yushar A, Razali M, Rahman RA, Ramli R. Incidental radiological findings of susuk in the orofacial region. *Dento Maxillo Facial Radiol.* 2006;35(6):473–4.
7. Shanmuhasuntharam P, Ghani SH. Susuks: Charm needles in facial soft tissues. *Br Dent J.* 1991;170(8):309–11.
8. Martin JL, Vlachou PA. Case 263: Malaysian Charm Needles (Susuk). *Radiology.* 2019;290(3):843–7.
9. Teo S. A woman with hidden charm needles. *J R Coll Physicians Edinb.* 2006; 36(3):211–2.
10. Kanneppady S, Sham S, Lakshman A, Phaik K, Shetty S. The charming tale of charm needles! *Nitte Univ J Health Sci.* 2017;7:66–8.
11. Tandjung YRM, Hong CP, Nambiar P, Ibrahim N. Uncommon radiological findings: A case report. *Int Dent J.* 2007; 57(3):173–6.
12. Loh FC, Ling SY. Analysis of the metallic composition of orofacial talismans. *Oral Surg Oral Med Oral Pathol.* 1992;73(3): 281–3.
13. Arishiya T, Mohammed F. Susuk - black magic exposed "white" by dental radiographs. *J Clin Diagn Res JCDR.* 2014;8(7):ZD03–4.
14. Varghese E, Samson RS, Nagraj SK, Chandrappa PR. Susuk or charm needle: A strange object detected on orthodontic diagnostic radiographs. *BMJ Case Rep;* 2017.
15. Balasundram S, Yee SCM, Shanmuhasuntharam P. Susuk: Charm needles in orofacial soft tissues. *Open J Stomatol.* 2013;3(2):155–62.

© 2020 Umesan et al.; This is an Open Access article distributed under the terms of the Creative Commons Attribution License (<http://creativecommons.org/licenses/by/4.0>), which permits unrestricted use, distribution, and reproduction in any medium, provided the original work is properly cited.

Peer-review history:
The peer review history for this paper can be accessed here:
<http://www.sdiarticle4.com/review-history/59325>