



## **Sub-Chronic Hepatotoxicity in Adult Wistar Rats Following Administration of *Ocimum gratissimum* Aqueous Extract**

**A.J. Ajibade<sup>1\*</sup>, P.B. Fakunle<sup>1</sup>, L.O. Ehigie<sup>2</sup> and A.O. Akinrinmade<sup>1</sup>**

<sup>1</sup>Department of Anatomy, Ladoké Akintola University of Technology Ogbomoso,  
Oyo State, Nigeria.

<sup>2</sup>Department of Biochemistry, Ladoké Akintola University of Technology Ogbomoso,  
Oyo State, Nigeria.

Research Article

Received 30<sup>th</sup> July 2011  
Accepted 17<sup>th</sup> September 2011  
Online Ready 9<sup>th</sup> December 2011

### **ABSTRACT**

**Background & Aims:** *Ocimum gratissimum* is an herbaceous plant commonly found in tropical Asia and in the coastal areas of Nigeria, where it is used for the treatment of ailments such as diarrhoea, urinary infections, fever and dysentery. However, information concerning the toxic effect of continuous administration of aqueous preparation of *Ocimum gratissimum* on some important organs of the body such as the liver is lacking. The study was designed to evaluate the effects of oral administration of the aqueous extract of *Ocimum gratissimum* at varying doses on the liver of adult male wistar rats.

**Materials and Methods:** The rats (n=30) of average weight of 185g were randomly assigned into four treatment groups A, B, C, D (n=6) and control group E (n=6). Aqueous extract of leaves of *Ocimum gratissimum* (OG) at doses of 0.4, 0.8, 1.6 and 3.2 g/kg body weight were administered orally to the four treatment groups A, B, C and D respectively for twenty one days. The control rats received quantities of distilled water equivalent to those in the treatment groups. The rats were sacrificed on the twenty second day of the experiment. The abdomen of the rats were carefully dissected and some blood was carefully collected by cardio-puncture into lithium heparinized sterile bottles for biochemical enzyme assay, also the liver was carefully dissected out and quickly fixed in 10% formol saline for routine histological study using haematoxylin and eosin method. Decrease in body weights of the treated, rats at the end of the study were statistically significant ( $p < 0.05$ ) in the treatment groups B, C and D.

**Results:** The histological findings after H&E method indicated that the treated sections

\*Corresponding author: Email: [adeshinaajibade@yahoo.co.uk](mailto:adeshinaajibade@yahoo.co.uk);

of the liver showed evidence of dilations of the central veins, which contained lysed red blood cells and cyto-architectural distortions of the hepatocytes, cytoplasmic hemorrhage, atrophic and degenerative changes. The biochemical results showed finding in line with the histopathological analysis. Quantitative analysis of serum liver enzymes in the treated' groups A, B, C and D showed significant increase ( $P < 0.05$ ) in the serum levels of Alanine aminotransaminase, aspartate aminotransaminase and alkaline phosphatase as compared to the control (untreated) groups.

**Conclusion:** These findings indicate that high doses of aqueous extract of *Ocimum gratissimum* may have some adverse effects on the liver of adult wistar rats which may ultimately impair hepatic functions.

*Keywords:* Liver; *Ocimum gratissimum*; enzymes distortion; hepatocytes; dilations; central veins.

## 1. INTRODUCTION

Medicinal plants have being used for centuries before the advents of orthodox medicine. Leaves, flowers, stems, roots, seeds, fruits and bark can all be constituents of herbal medicines (Afolabi *et al.*, 2007). The use of plants for medicinal purposes predates human history and forms the origin of modern medicine. Many synthetic drugs originated from plant sources (Vicker *et al.*, 1999). A century ago, most of the few effective drugs were plant-based, examples include: Aspirin (which is a chemical copy of the analgesic chemical in the bark of willow trees), Digoxin (from fox glove), Guanine (from the bark of various cinchona tree species which was used in the treatment of malaria) and Morphine (from the opium poppy) (Vicker *et al.*, 1999). Medicinal plants constitute an effective source of both traditional and modern medicine. Herbal medicine has been shown to have genuine utility, and about 80% of rural populations depend on it as their primary health care (World Health Organization, 1992). In Nigeria, various plant parts are used for curing different ailments with remarkable success. Among the enormous number of these medicinal plants are members of the genus *Ocimum* L. (Lamiaceae). The genus is represented by six species in West Africa (Hutchinson *et al.*, 1996). However, only three species, *O. gratissimum* L., *O. basilicum* L. and *O. canum* Sims have been reported to have medicinal properties (Olowokudejo *et al.*, 1998). The medicinal values of these plants lie in their component phytochemicals, which produce definite physiological actions on the human body (Afolabi *et al.*, 2007). *Ocimum gratissimum* L. is grown for the essential oils in its leaves and stems and various research works have been designed to evaluate the various potentials of extract from the leaves of *Ocimum gratissimum* and to explore its basis for traditional use. It is against this background, that the use of plant products in human medicine has become a thing of very keen interest.

The liver is the second largest organ in the body, contributing about 1/50 of the total body weight, or about 1.5 kg in the average adult human (Arthur *et al.*, 2005). It is a large chemical reactant pool of cells that have a high rate of metabolism, sharing substrates and energy from one metabolic system to another, processing and synthesizing multiple substrates that are transported to other areas of the body, and perform other metabolic functions (Arthur *et al.*, 2005).

The liver is especially important for maintaining a normal blood glucose concentration (This is called the glucose buffer function of the liver), synthesis and metabolism of fat and protein metabolism (Arthur *et al.*, 2005). The basic structural components of the liver are the hepatocytes which have one or two rounded nuclei with one or two typical nucleoli. Reports concerning the toxic effects of herbal medicine are associated with hepatotoxicity although the reports of other toxic effects on other organs and systems have been published in the medical literature (Basher *et al.*, 2006).

The active chemical medium of the liver is well known for its ability to detoxify or excrete into bile many drugs, including sulfonamides, penicillin and ampicillin (Arthur *et al.*, 2005). In a similar manner, several of the hormones secreted by the endocrine glands are either chemically altered or excreted by the liver. Liver damage can often lead to excess accumulation of one or more of these hormones in the body fluids and therefore can cause over-activity of the hormonal system (Arthur *et al.*, 2005).

The study of toxic or adverse effect of crude drugs of plant origin is essential in order to prove a guide to their safe usage and eventual standardization. This is especially pertinent as traditional medicine practitioners often administer such preparations without regards to their possible adverse effects. *Ocimum gratissimum* extract has been reported to have anti-diarrhea and anti-pyretic activities (Oliver, 1980; Sofowora, 1993). Besides, the extract has been used in the treatment of mental illness (Abdulrahman, 1992). Extract of *Ocimum gratissimum* has also been shown to have sedative activity (Effrain *et al.*, 1997) and to have therapeutic benefit in patients with inflammatory joint disease (Tanira *et al.*, 1988). However, there is paucity of information concerning the toxic or adverse effect of repeated or continuous administration of aqueous preparation of *Ocimum gratissimum* on some important organs of the body such as the liver. Therefore the study aims to study the sub-chronic hepatotoxicity in adult wistar rats following administration of *Ocimum gratissimum* aqueous extract.

## 2. MATERIALS AND METHODS

Thirty (30) male healthy wistar rats with an average weight of 185 grams were procured from the animal house, Department of Physiology, Ladoke Akintola University of technology. The rats were kept and maintained under standard laboratory conditions of temperature, humidity and light for a period of two weeks in the animal holdings of the Department of Human Anatomy, Ladoke Akintola University of Technology, Ogbomoso, Oyo-State before the commencement of the experiment. During this course, the rats freely fed on pellets from Ladoke Farms, Ibadan and were given distilled water *ad libitum*.

### 2.1 Experimental Design and Groupings

In the study, a total of 30 adult male Wistar rats were used. The rats were randomly separated into 5 groups of 6 rats each. Group A, B, C and D served as the experimental treated groups and received aqueous extract of *Ocimum gratissimum* at varying doses. Group E served as the control group and received the same quantity of distilled water as contained in the experimental doses.

Administration of the aqueous extract of *Ocimum gratissimum* was done orally by means of an oral canula. Group A, B, C and D received the aqueous extract of *Ocimum gratissimum* at doses of 0.4, 0.8, 1.6, 3.2 g/Kg body weights respectively five times a week for three weeks.

Rats in the control group (Group E) received quantity of distilled water as contained in the experimental doses.

At the end of the study (end of the third week), the rats were sacrificed by cervical dislocation. The abdomen of each rat was carefully dissected. The heart was located in the thoracic cage and 2 mls of blood was carefully collected from the apex of the heart using a needle mounted on 5 ml syringe (Becton Dickinson S.A., Fraga, Spain). Blood samples were collected into lithium heparinized sterile bottles. These were used for biochemical assay of alkaline phosphatase (ALP), alanine aminotransaminase (ALT) and aspartase aminotransaminase (AST) following the methods of Varley et al., (1980) and Haussament, (1977). The liver was also removed and observed grossly. It was immediately fixed in 10% buffered formol saline for histological studies. Tissue processing for light microscopy was carried out using the methods of Carleton (1967). Permanent micrographs of the desired sections were obtained to record morphologic observations using a digital camera. The observations were made using an Olympic research microscope.

## 2.2 Statistical Analysis

The data obtained were analyzed using statistical analysis of the variance. Group data difference was evaluated by the student's t-test at 95% confidence level. All results were expressed as Means  $\pm$  S.E.M.  $P < 0.05$  was accepted as significant in this study.

## 3. RESULTS

The pattern of weight changes in the various groups of the wistar rats before the treatment and during the treatment is shown in Figure 1.

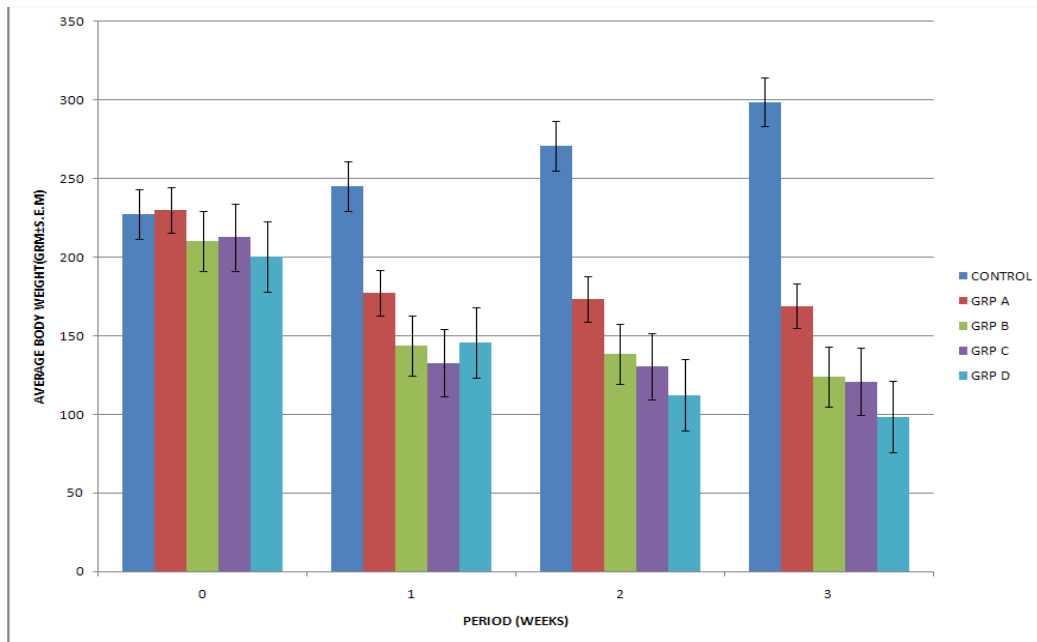


Figure 1: Histogram showing the relationship between the average body weights of rats in the treated groups in relation to the control group

A dose-response relationship is indicated in the weight changes following treatment. The figure depicts adverse effects of aqueous extract of *Ocimum gratissimum* on the rat body weights which evidently decreased in a duration and dose-dependent manner. The weights of the control rats increased appreciably from the beginning of the study to the end. Conversely, the weights of the treated rats decreased from the beginning of the treatment to the end.

### 3.1 Biochemical Analysis of Hepatic Enzymes

The results of the biochemical analysis of liver enzymes are depicted in Table 1. It shows the average (n=3) levels of the biochemical parameters for liver function test (LFT). Laboratory analysis of blood samples revealed a significantly elevated levels of serum transaminases and alkaline phosphatase in the treated groups (A, B, C and D), ( $p < 0.05$ ) as compared with the control (group E). Elevations in values tend to be dose dependent. The serum levels of all the three hepatic enzymes increased significantly in all the treated rats compared with the control (Table 1 and figure 1).

**Table 1: Average serum levels of aspartate aminotransferase (AST), alanine aminotransferase (ALT) and alkaline phosphatase (ALP) in *Ocimum gratissimum* treated rats relative to the control group**

Hepatic Enzymes	Average serum levels (IU/L)				
	Control group	Group A	Group B	Group C	Group D
AST	12.00 ± 1.52	24.00 ± 1.00*	32.33 ± 2.85*	36.66 ± 4.81*	47.66 ± 7.31*
ALT	5.00 ± 0.58	7.66 ± 1.45	10.33 ± 2.33*	10.33 ± 2.96*	23.00 ± 1.73*
ALP	22.33 ± 1.45	27.33 ± 3.84*	30.00 ± 2.19*	37.66 ± 0.58*	55.00 ± 7.64*

Values are Mean ± S.E.M; Significantly different from control group, \* =  $P < 0.05$

### 3.2 Histological Observations

General histopathological evaluation of the liver, revealed a dose-dependent effect of the extract on the histo-architecture of the liver, with the effect increasing with dose.

The sections of the liver tissue from the control group showed normal histological features. The pericentral region of the hepatic lobule showed preserved cytoplasmic architecture with hexagonal lobules consisting of central vein and radially arranged hepatocytes. The sinusoids lined with endothelial cells were also present (Plate 1B). At the periphery of the hepatic lobule, the hepatic portal veins, bile duct and hepatic artery within the portal tract were all visible (Plate 1A).

The photomicrograph of sections from the rats in group A treated rats showed that the hepatocytes were swollen with the sinusoidal spaces occluded at both the pericentral and periportal region of the hepatic lobule. The hepatic plates were seen to converge and anastomose around the central vein, the latter was also seen to be surrounded by few kupffer cells (Plate 2A and 2B).

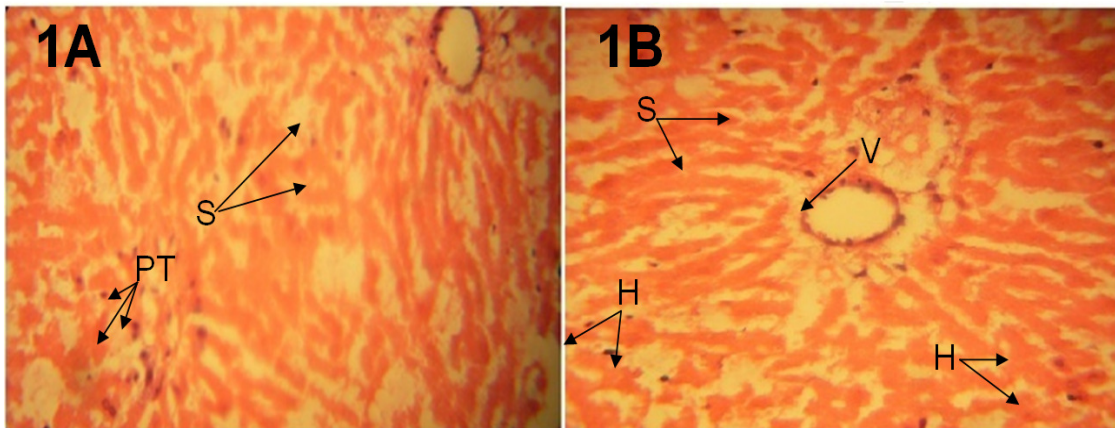
Sections of the liver from rats in group B administered with 0.8 gkg<sup>-1</sup> body weight of the extract showed marked dilatation of the central vein with lysis of the red blood cells. Very few mononuclear mature and diffuse lymphocytes were noticed (Plate 3A and 3B).

Group C treated with  $1.6 \text{ gkg}^{-1}$  body weight of the aqueous extract of *Ocimum gratissimum* presented hemorrhagic necrosis at the periportal region of the hepatic lobule. Dilatation of the central vein with lysis of the red blood cells was also evidenced in this group. Degenerative activities of the liver were evidenced by the presence of prominent Kuffer cells, lymphocytes within the sinusoids and few eosinophils within the portal areas (Plate 4A & 4B).

The histopathology result observed from photomicrographs taken from sections of the liver from rats in group D, administered with  $3.2 \text{ gkg}^{-1}$  body weight of the extract showed atrophic and degenerative changes with severe cytoplasmic hemorrhage at the pericentral region. Fragmentation of the hepatic lobule was also evidenced as compared to the control. The hepatocytes at the periportal region showed marked thickness (Plate 5A & B).

### 3.3 Histological Plates

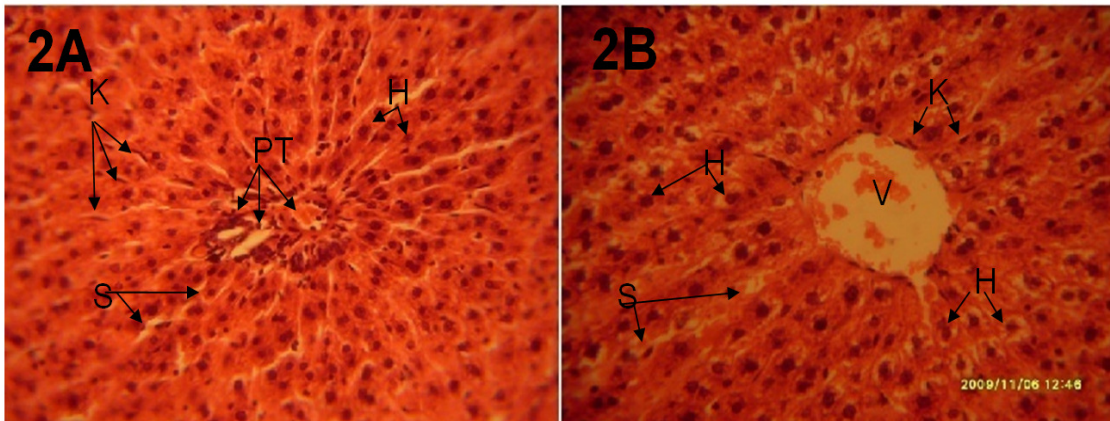
The histological plates obtained from the control and treated sections of the liver are shown below.



**Plate 1. Light photomicrograph of sections from the liver of rats in the control group.**

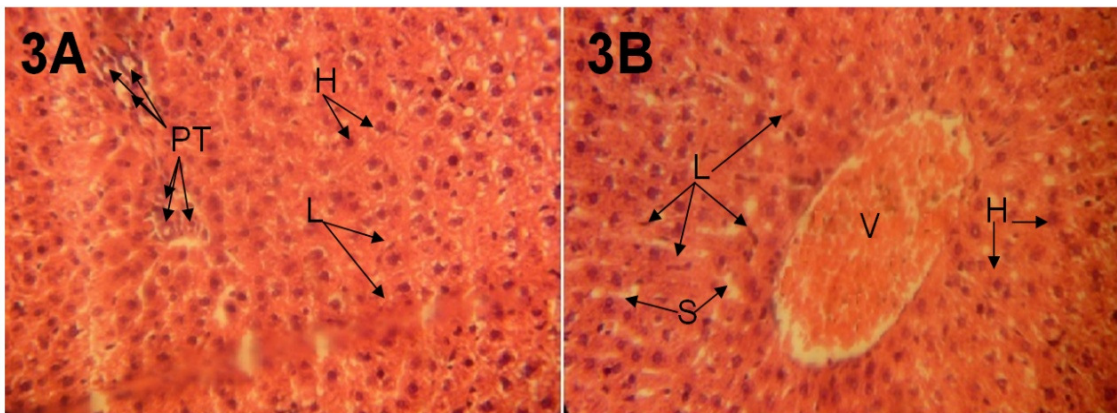
*Plate 1A and 1B showing the normal histological features around the periportal and pericentral regions of the hepatic lobule respectively. Showing the central vein (V), the hepatocytes (H) interacting with the hepatic sinusoids (S) and the portal tract (PT). (H&E x 400)*





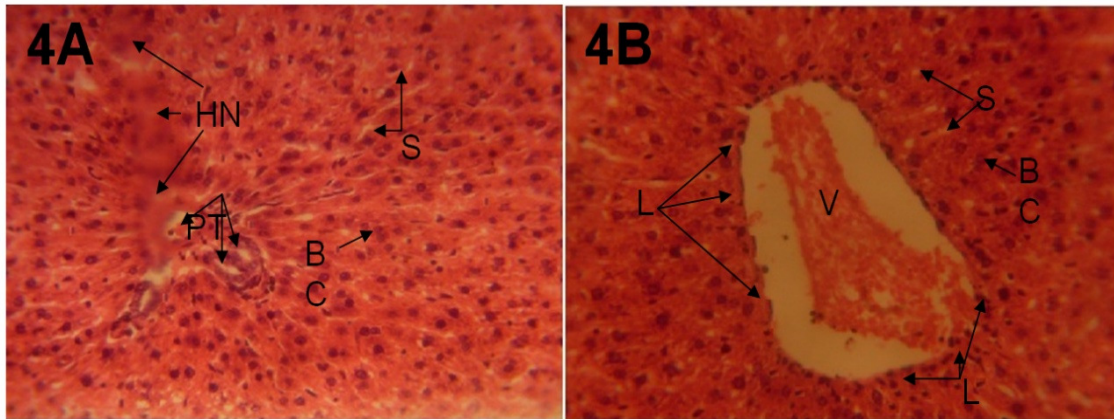
**Plate 2. Light photomicrograph of sections from the liver of rats administered with 0.4 gkg<sup>-1</sup> body weight of the aqueous extract of *Ocimum gratissimum*.**

*Plate 2A and 2B showing the periportal and pericentral region of the hepatic plates respectively. Section shows the dilated central vein (V), occluded sinusoidal spaces (S), swollen hepatocytes (H). Cellular infiltration noticed around the central vein and portal tract (PT). (H&E x 400)*



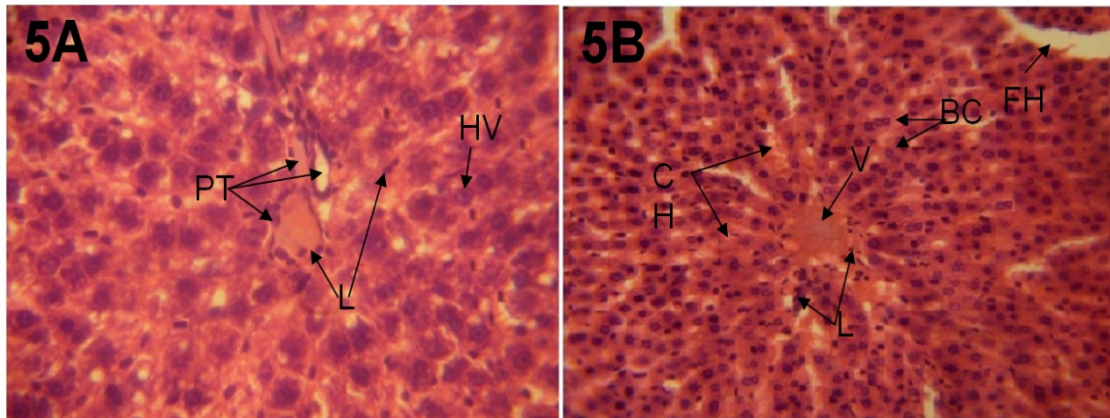
**Plate 3. Light photomicrograph of sections from the liver of rats administered with 0.8 gkg<sup>-1</sup> body weight of the aqueous extract of *Ocimum gratissimum*.**

*Plate 3B showing a dilated central vein (V) with lysed red blood cells. The hepatocytes (H) were more swollen, occluded sinusoidal spaces (S) and few lymphocytic infiltrations (L) were evidenced in Plate 3A and 3B as compared to the control group (Plate 1A and 1B). (H&E x 400)*



**Plate 4. Light photomicrograph of sections from the liver of rats administered with 1.6 gkg<sup>-1</sup> body weight of the aqueous extract of *Ocimum gratissimum*.**

*As evidenced in plate 4A and 4B of the light photomicrograph: hemorrhagic necrosis (HN) around the periportal region, marked dilation of the central vein (V) with lysed red blood cells, occluded sinusoidal spaces (S), binucleated hepatocytes (BC), intense cellular infiltration (L) around the central vein and portal tract (PT) was observed in this group. (H&E x 400)*



**Plate 5. Light photomicrograph of sections from the liver of rats administered with 3.2 gkg<sup>-1</sup> body weight of the aqueous extract of *Ocimum gratissimum*.**

*Plate 5A and 5B showing that the liver had lost its characteristics architecture both at the periportal and pericentral regions. The photomicrograph presented severe dilation of the central vein (V) resulting in cytoplasmic hemorrhage (CH), Fragmentation of the hepatic lobule (FH), intense cellular infiltration (L), hepatocytic vacuolation (HV) and binucleate hepatocytes (BC). (H&E x 400)*

#### 4. DISCUSSION

Herbal remedies are widely used for the treatment and prevention of various diseases and often contain highly active pharmacological compounds. Many medicinal herbs and pharmaceutical drugs are therapeutic at one dose and toxic at another. Toxicity related to



traditional medicines is becoming more widely recognized as these remedies become popular in the Mediterranean region as well as worldwide (Bashar *et al.*, 2006). Reports concerning the toxic effects of herbal medicines are associated with hepatotoxicity, although reports of other toxic effects including kidney, nervous system, blood, cardiovascular and dermatologic effects, mutagenicity and carcinogenicity have also been published in the medical literature (Bashar *et al.*, 2006).

*Ocimum gratissimum* as an herbal plant is widely distributed throughout Central America, West African coast and has been used in Trinidad and Tobago and in Nigeria for the treatment of various ailments including diabetes mellitus (Bailey and Day, 1989; Aguiyi *et al.*, 2000). Previous work revealed that the aqueous extract of *Ocimum gratissimum* possesses antipyretic and anti-diarrhea activities (Oliver, 1980; Sofowora, 1993).

The present study shows that administration of the aqueous extract of *Ocimum gratissimum* may result in histopathological changes in critical organs such as the liver when administered in varying doses (0.4, 0.8, 1.6 and 3.2 g/kg body weight) of the extract.

The results of the haematoxylin and eosin staining (H & E) reactions revealed that with increasing dose of aqueous extract of *Ocimum gratissimum*, there was varying degrees of dilatations of the central vein of the liver which contained lysed red blood cells in the treatment sections compared with the control section of the liver. The necrosis observed is in consonance with the findings recorded in the work carried out by Efiri (2009), where it was noted that aqueous extract of *Ocimum gratissimum* adversely affected the lungs of adult wistar rats.

The proliferating cells of the liver, which produce red and white blood cells, are normally found between the hepatic cells and the walls of the vessels (Singh, 1997). As a result of the distortion and dilatation of the hepatocytes and their central vein in the treated rats, the haemopoetic function of the liver may have been adversely affected as a result of probable toxic effect of aqueous extract of *Ocimum gratissimum*.

Cellular degeneration has been reported to result in cell death, which is of two types, namely apoptotic and necrotic cell death. These two types differ morphologically and biochemically (Wyllie, 1990). Pathological or accidental cell death is regarded as necrotic and could result from extrinsic insults to the cell such as osmotic, thermal, toxic and traumatic effects (Farber *et al.*, 1981). Cell death in response to toxins occurs as a controlled event involving a genetic programme in which caspase enzymes are activated (Waters *et al.*, 1994).

As the hepatocytes swells as seen in this study the activities of cellular transporters might be modified by up or down regulations as earlier reported in the case of hyponatremia or hypernatremia (Johnson, 1995). Ischaemic or pharmacologic disruption of cellular transporters can cause swelling of parenchyma of the liver cells. The disruption caused by aqueous extract of *Ocimum gratissimum* is a cardinal feature of the results of this study. Though there are many different causes of cell swelling including drug poisoning, water intoxication, hypoxia from asphyxia and acute hyponatremia (Johnson, 1995). Aqueous extract of *Ocimum gratissimum* may have acted as toxins to the hepatocytes, affecting their cellular integrity and causing defect in membrane permeability and cell volume homeostasis.

The cellular hypertrophy observed in the treated sections may have been caused by the cytotoxic effect of aqueous extract of *Ocimum gratissimum* on the liver. This obviously may alter the detoxification processes and other liver functions. Also, the presence of many

binucleate hepatocytes in the treated sections of groups C and D may result in cell unrest, probably as a reaction to a toxic agent in the aqueous extract.

The body weights of the wistar rats in the treatment groups B, C and D significantly decreased in relation to the increasing concentration of the extract, which produced a dose and time dependent decrease in body weight over the 3 weeks period of administration of the extract. This result agrees with the work of Vale et al., (1995) where they reported that increased intake of medicinal herbs among men over a period of 6 months caused a decrease in their body weight.

One of the signs of hepatic injury or damage is apparent leakage of cellular enzymes into plasma. In addition, the extent and type of liver injury or damage can be assessed based on the presence or absence of specific enzymes in the blood stream (Jens, 2002). In general measurement of alanine aminotransaminase (ALT), aspartate aminotransaminase (AST) and alkaline phosphatase (ALP) are commonly used as marker enzymes in accessing drug induced hepatotoxicity (Moorthy et al., 2009). Measurement of ALT is more liver specific to determine hepatocellular damage (Jens, 2002).

The biochemical investigations carried out in this study revealed markedly significant ( $p < 0.05$ ) elevated levels of serum liver enzymes in treated rats. The greater the values of these parameters, the greater the damage on the liver cells which results in a decreased liver activities. Elevated levels of serum aspartate aminotransaminase (AST) and serum alanine transaminase (ALT) are indications of hepatocellular injury. As depicted in table 2 above, the elevated levels of AST and ALT were highest in the treatment group D that received 3.2 g/kg body weight of the aqueous extract of *Ocimum gratissimum*. The decrease in enzymes levels appears to be dose dependent. These findings are consistent with earlier report of toxic potentialities of essential oil of *Ocimum gratissimum* (Orafidiya et al., 2004). The observable liver pathological changes coupled with significant increased in enzymes levels in the treated rats may have resulted from the toxicity potentials of the extract administered. The dose - response elevated levels of the hepatic enzymes in the treated rats have shown a dose-response relationship with hepatic injury, consequently, changes in hepatic enzymes level appear to be sensitive indicators of a dose -response relationship in cases of hepatic injuries.

## 5. CONCLUSION

The results obtained in this study revealed that aqueous extract of *Ocimum gratissimum* at high doses adversely affect liver morphology. The hepatocytes of the liver of the wistar rats that received high doses of the aqueous extract showed some degenerative changes, and cellular hypertrophy as well as reduced body weight and markedly significant ( $p < 0.05$ ) high levels of serum liver enzymes (ALT, AST, ALP). With this result, it is not impossible that the functions of the liver as a major metabolic organ may be adversely affected. It is recommended that further studies be carried out to corroborate these findings.

## COMPETING INTERESTS

Authors have declared that no competing interests exist.

## REFERENCES

- Abdulrahman, F. (1992). Studies in Natural Products. The Moraceae In African Traditional Medicine and Management of Psychiatry In Borno State. M.Sc. Thesis. Department of Chemistry, Univ. of Maidugurl., Pp. 89-94.
- Afolabi, C.A., Ibukun, E.O., Emmanuel, A., Obuotor, E.M., Farombi, E.O. (2007). Phytochemical constituent and antioxidant activity of extract from the leaves of *Ocimum gratissimum*. Scientific Research and Essay, 2(5), 163-166.
- Bailey, C.J., Day, C. (1989). Traditional Plant medicines as treatment for diabetes. Diabetes Care, 12, 553-564.
- Bashar, S., Hassan, A., Ghassan, A.H., Omar, S. (2006). Safety of Traditional Arab Herbal Medicine. Evid Based Complement Alternate Med. PMID, PMC1697757.
- Carleton's Histological Techniques, 4<sup>th</sup> ed., Oxford University Press NY. U.S.A., 1967, 279-280.
- Efiri, E.C. (2009). The effect of *Ocimum gratissimum* on the histology of the lungs of albino rats. <http://christopher-efiri.blogspot.com/02/effect-of-ocimum-gratissimum-on.html>.
- Effrain, K.D., Jacks T.W., Sodipo O.A. (1997). Histopathological studies on the toxicity of *Ocimum gratissimum* leave extract on some organs of Rabbits: African Journal of Biomedical Research, 6, 21-25.
- Farber, J.L., Chein, K. R., Mitnacht, S. (1981). The pathogenesis of irreversible cell injury in ischemia. Am J Pathol., 102(2), 271-281.
- Haussament, T.U. (1977). Quantitative determination of serum alkaline phosphatase. Clin. Chem. Acta, 35, 271-273.
- Hutchinson, J., Dalziel, M.D. (1996). Flora of West Tropical Africa. London, p.148
- Jens, J.J., Hanne, H. (2002). The Danish Hepatitis C web site, about blood tests. Overall view Of Liver Function Tests. <http://www.janis7hepc.com/labs2.htm>.
- Johnson, C.E. (1995). Effects of fluid imbalances: Neurosciences in Medicine: P. Michael conn JB Lippincott Company, pp. 187.
- Oliver, B. (1980), Medicinal Plants in Nigeria. Published by Nigerian College of Arts, Science and Technology, Ibadan, Pp. 90-94.
- Olowokudejo, J.D., Pereira-Sheteolu, O. (1998). The taxonomic value of epidermal characters in the genus *Ocimum* (Lamiaceae). Phytomorphol., 38, 147-58
- Orafidiya, L.O., Agbani, E.O., Iwalewa, E.O., Adelusola, K.A., Oyedapo, O.O. (2004). Studies on the acute and sub-chronic toxicity of the essential oil of *Ocimum gratissimum* L. leaf. Phytomedicine: International Journal of Phytotherapy & Phytopharmacology, Pp. 176-180
- Singh, I. (1997). Textbook of human histology with colour atlas. Third Edition, Jaypee Brothers Medical Publishers Ltd. Pp., 238-244.
- Sofowora, L. A. (1993). Medicinal plants and traditional medicine In Africa, 3 Mn. Spectrum books Ltd, Ibadan, Pp. 55-71.
- Tanira, M.M., Aged, A.M., Tang, M., Moshin, A., Shah, N. (1988). Evaluation of some pharmacological and physical propertie of zlvphns spina chuisti InC 3. Crude Drug Res., 26(1), 56-60.
- Varley, H., Gowenlock, A.H., Bell, M. (1980). Practical Clinical Biochemistry, Vol. 1 (5th ed.), pp., 741-742, 892-908. W. Heinemann, London.
- Vicker, A., Zollman, C. (1999). *Ocimum gratissimum* (South-EastAsian-Tree-Basil) [www.zipcodezoo.com/plants/O/Ocimum\\_gratissimum](http://www.zipcodezoo.com/plants/O/Ocimum_gratissimum).
- Waters, C.M., Wakinsshaw, G., Moser, B., Mitchell, I.J. (1994). Death of Neurons in the neonatal rodent globus pallidus occurs as a mechanism of apoptosis. Neuroscience, 63, 881-894.

- World Health Organisation. (1992). The promotion and development of traditional medicine. Geneva: World Health Organization, 1992. (Technical report series no. 622).
- Wyllie, A.H. (1990). Glucocorticoid-induced thymocyte apoptosis is associated and endogenous endonuclease activation. *Nature*, London, 284, 555-556.
- Valey, J.A., Proudfoot, A.T., Lancet. (1995). Nutritional values of medicinal herbs. *American Journal of Clinical Nutrition*, 42, 289-295.

---

© 2012 Ajibade et al.; This is an Open Access article distributed under the terms of the Creative Commons Attribution License (<http://creativecommons.org/licenses/by/3.0>), which permits unrestricted use, distribution, and reproduction in any medium, provided the original work is properly cited.