



Lateral Soft Tissue Neck X-ray a Tool for the Otorhinolaryngology Surgeon

Ibekwe Matilda Uju^{1*} and Oghenekaro Edirin¹

*¹Department of Ear Nose and Throat Surgery, University of Port Harcourt Teaching Hospital,
Port Harcourt, Rivers State, Nigeria.*

Authors' contributions

This work was carried out in collaboration between both authors. Author OE collated and analysed the data. Author IMU designed, interpreted and prepared the manuscript. Both authors read and approved the final manuscript.

Article Information

DOI: 10.9734/IJTDH/2019/v39i230201

Editor(s):

- (1) Dr. Pradosh Kumar Sarangi, Department of Radiodiagnosis, S.C.B. Medical College and Hospital, Cuttack, India.
- (2) Dr. Payala Vijayalakshmi, Department of Microbiology, Gitam Institute of Medical Sciences and Research, Gitam University, India.
- (3) Dr. Shankar Srinivasan, Associate Professor, Department of Health Informatics, Rutgers - School of Health Professions, USA.

Reviewers:

- (1) Vinay Marla, Penang International Dental College, Malaysia.
 - (2) Endah Rahayuningsih, Center for Economics and Development Studies, Padjadjaran University (CEDS UNPAD), Indonesia.
 - (3) Mariappan Natarajan, Sri Ramachandra Institute of Higher Education and Research, India.
- Complete Peer review History: <http://www.sdiarticle4.com/review-history/52355>

Original Research Article

Received 01 September 2019
Accepted 04 November 2019
Published 14 November 2019

ABSTRACT

Background: Management of aerodigestive emergencies can prove a challenge especially in this sub-Saharan region where there is a dearth of specialized equipment. In some areas, a plain radiograph may be the only investigative tool readily available to the surgeon. It is routinely done in most of these cases. In our environment health care is often financed by the patients through out of pocket expenses since most do not have health insurance. Affordability of a particular treatment becomes paramount. This study, therefore, is aimed at assessing the use of lateral soft tissue neck X-ray and its reliability as a diagnostic tool in aerodigestive emergencies.

Objective: To determine the relevance or effectiveness of plain radiograph of the lateral soft tissue neck in patients with upper aerodigestive emergencies and therefore its use as a tool to the otorhinolaryngology (ORL) surgeon as the first-line investigation in these patients.

*Corresponding author: Email: ibekwe_uju@yahoo.com;

Patients and Methods: It is a prospective study of all patients that presented to the ENT surgery department of UPTH from April 2018 to April 2019 with upper aerodigestive emergencies. Patients who presented in the ENT clinic, accident and emergency department, children's emergency wards and the clinics with upper aerodigestive emergencies were recruited in this study. All the patients had X-ray lateral soft tissue of the neck done on presentation and the results were then compared with the final operative findings in the operation theatre. Some patients had also chest radiograph done however; the diagnosis was done based on the lateral soft tissue neck finding. Patients that had radiologic investigation other than radiograph of the lateral soft tissue neck as the main investigative tool were excluded from the study. The radiologist opinion was obtained for all the radiographs as a routine. The results were analyzed using the SPSS 20 and presented in simple statistical tables.

Results: Sixteen patients were studied. Males were 14(87.5%) while females were 2(12.5%). Age range was from 1.5 to 77 years with children comprising only 31.25% of the study population. The commonest presenting complaint was voice change 68.75%. Positive findings on the x-ray neck were seen as soft signs in 62.5% and radio-opacity in 18.75%. In n=14(87.5%) the lateral neck x-ray positive findings were corroborated by the operative findings. The tool has a specificity of 100% for both foreign body inhalation/ingestion and laryngeal tumour but the sensitivity of 80% in laryngeal tumours but 100% for the foreign body.

Conclusion: Study concludes that lateral soft tissue neck x-ray was found to be a good and useful tool in the diagnosis of a good number of upper aerodigestive emergencies such as foreign body ingestion/inhalation and patients with upper airway obstruction caused by laryngeal tumours and some infective conditions such as a retropharyngeal abscess.

Keywords: Otorhinolaryngology; radiograph; laryngeal tumours; aerodigestive emergencies.

1. INTRODUCTION

Upper aerodigestive tract emergencies are notable causes of morbidity and mortality especially in children and the elderly [1]. Common causes of these emergencies include foreign body inhalation/ingestion which tends to occur commonly in the paediatric population [2] others are blunt and penetrating trauma to the neck from road traffic accidents, gunshots, cutthroat injuries, tumours causing airway obstruction, corrosive ingestions and acute tonsillitis with its complications [3,4]. They often present as life-threatening conditions and therefore do not leave room for extensive investigations before definitive interventions. There is, therefore, need to have access to at least one reliable and readily available investigative tool that can help confirm the diagnosis and therefore determine the line of management.

In our environment, the plain radiograph is still the mainstay or main radiologic investigative tool employed due to its affordability. The reliability of this tool becomes of paramount importance especially in these patients where it may be difficult to obtain a reliable history so the diagnosis will depend on clinical assessment and radiologic investigation.

The most useful radiological view of the laryngopharynx is the lateral soft tissue neck x-ray [5]. It can differentiate a foreign body in the oesophagus from that in the tracheobronchial region, unlike the anteroposterior view [6]. A normal lateral soft tissue neck radiograph will show the pharynx, larynx and trachea properly. It will also show the normal width of the prevertebral soft tissues and cervical spine normal in height and alignment. It is noninvasive, readily available, well-tolerated by patients, relatively cheap and can easily be carried out [6]. In some upper aerodigestive conditions, it can be quite useful, for instance in foreign body ingestion which is a common problem in both adults and children [7,8]. In patients with suspected foreign body ingestion, lateral soft tissue neck radiograph is the first line of imaging tool employed in these emergencies. Visualization of these foreign bodies depends on the location and the radiopacity. Radiopaque foreign bodies can be easily diagnosed on the lateral soft tissue neck radiograph. The non-radiopaque foreign bodies do not show on lateral soft tissue neck radiograph but are often diagnosed based on the presence of soft signs such as; widened prevertebral shadow, loss of cervical lordosis and gas shadows. Radio-opacity is said to be a far more reliable sign than the soft signs in lateral soft tissue neck radiograph [6]. It is known that about 80-90% of

all these foreign bodies will pass spontaneously through the digestive tract but about 10-20% may require some interventions [9] and foreign body ingestion carries significant morbidity and mortality due to possibility of serious complications [10]. Therefore for foreign bodies in the upper aerodigestive tract, lateral soft tissue neck X-ray is a tool for making the diagnosis but its total reliability is debatable [11]. In spite of its limited clinical utility, the lateral soft tissue neck radiograph is the most common first-line investigation in cases of suspected foreign body ingestion/inhalation [12,13]. It is, therefore, an available investigation of clinical value in assessing patients with upper aerodigestive pathology and it is useful in both acute and chronic situations [13]. In a study in Singapore however, a false negative value of 67.9% was found with plain lateral soft tissue neck x-ray [14]. Siva, et al. in their study found the reliability to be poor in detecting airway foreign bodies with low sensitivity and specificity [15]. In another study, however, plain x-rays of the soft tissue of the neck were found to be very useful in airway foreign body with high sensitivity and specificity (100%) when compared with bronchoscopic findings [11]. Radiologic evaluation, in general, is helpful in the location of and possible detection of complications from foreign body ingestion [16]. It has been found that the smooth foreign bodies tend to lodge often at or below the cricopharyngeus muscle [17]. The radiographic findings in aspirated foreign bodies differ with the location and extent of obstruction [18]. In addition, normal ossifications or calcifications in the larynx can be mistaken for foreign bodies hence careful evaluation and interpretation of the lateral soft tissue neck x-ray is required in these conditions [19]. Karnwal et al. found in their study that there was a high number of misinterpretation by doctors both in accident & emergency and ENT department, therefore proper knowledge is essential for the interpretation of X-rays soft tissue neck [*19].

2. PATIENTS AND METHODS

This was a hospital-based non-randomized observational study involving patients with upper aerodigestive emergencies that presented to the ENT Surgery department of the University of Port Harcourt Teaching Hospital, Port Harcourt (UPTH) from April 2018 to April 2019. Upper aerodigestive emergencies are emergencies involving the upper airway and the upper or cervical oesophagus. Patients with upper aerodigestive emergencies that were referred

from the accident and emergency (A&E) department, Children emergency ward (CHEW) and those seen in the clinics during the period under study were recruited. Plain radiograph (X-ray) of the lateral soft tissue of the neck was done on presentation or admission. Inclusion criteria; patients are seen in the ENT clinic and referrals to the department through A&E, CHEW and general practitioners with a history of upper aerodigestive emergency and had lateral soft tissue neck X-ray done on admission or presentation. Patients with upper aerodigestive emergencies without X-ray soft tissue neck or other forms of imaging tools were excluded.

2.1 Sample Size Calculation

Using the finite population correction method for sample size calculation [20], based on the 95% confidence level and prevalence of hospital-based upper aerodigestive emergencies of 0.61% [21], a minimum sample size of 13 was deemed adequate.

2.2 Statistical Analysis

IBM Statistical Package for Social Sciences 20.0 was used for data analysis. Data were summarized using means, median and ranges for numerical variable while categorical variables were expressed as proportions. The summary table was used to present concise findings of radiograph and direct laryngoscopy. The difference in proportions was compared using Fisher's exact. The validity of soft tissue plain radiograph in comparison to oesophagoscopy/laryngoscopy was determined using sensitivity, specificity, positive and negative predictive values. A p-value of less than 0.05 was considered statistically significant. Kappa statistics were performed to assess the level of agreement between the tools (soft tissue radiograph and oesophagoscopy/ direct laryngoscopy). Confidence intervals were determined at the 95% level and alpha set at 0.05.

3. RESULTS

A total of 16 patients met the inclusion criteria. There were 14(87.5% 0 males and 2(12.5) females giving a male to female ratio of 7:1. The age range was from 1.5-77 years. Children comprised only 31.5% while adults made up 68.75% [Table 1]. The mean age of the study was a 38.98±28.45 year with a median of 40.50 years.

The commonest presenting complaint was voice change in 68.8% followed by dysphagia [Fig. 1].

Findings of soft signs in the lateral soft tissue x-rays were more than outright radio-opacity. In n=10(62.5%), the diagnosis from the x-ray was based on the presence of soft signs; prevertebral space widening in 6cases with air entrapment and loss of cervical lordosis, soft tissue shadow was seen in another 6 cases while diagnosis based on radio-opacity was seen in only 3 patients Table 2.

Table 1. Comparison of age category (Child/adult) by sex

Age category	Sex		Total n (%)
	Male n (%)	Female n (%)	
Child	4 (80.0)	1 (20.0)	5 (100.0)
Adult	10 (90.9)	1 (9.1)	11 (100.0)
Total	14 (87.5)	2 (12.5)	16 (100.0)

Fisher's exact p-value= 1.000

Majority of the x-ray report n=14(87.5%) was confirmed by the operative findings. Endoscopy; oesophagoscopy/laryngoscopy was carried out in 14 out of the 16 patients. Pharyngoscopy was done for patients with retropharyngeal abscess. Endoscopy was not possible in two patients; one with a huge neck mass that was diagnosed as thyroid mass and another patient who had gunshot injury to the neck. Foreign body ingestion/inhalation and laryngeal tumours were the highest aerodigestive emergencies seen in the study population comprised 37.50% respectively [Fig. 2]. The commonest foreign body in the study was dentures [Table 3].

In making the diagnosis of foreign body inhalation, lateral soft tissue neck x-ray had a sensitivity of 100%, specificity was 100%, positive predictive value 100% and the negative predictive value was also 100%. However, in that of the laryngeal tumour, the sensitivity 80.0% while specificity was 100%. The predictive values here were 88.9% for negative and 100% for positive [Tables 4 and 5].

Table 2. Summary of soft tissue X-ray report and oesophagoscopy/laryngoscopy findings and diagnosis

Soft tissue neck X-ray report	Oesophagoscopy/laryngoscopy	Diagnosis
Prevertebral space widening and air entrapment (n=3)	Presence of denture just below the cricopharyneus (n=3)	Foreign body ingestion
Radiopaque foreign body in the oesophagus (n=2)	Presence of metallic foreign body in the cricopharynx (n=2)*	Foreign body ingestion
Radiopaque foreign body at the level of C5-C6 (n=1)	Presence of metallic foreign body in the larynx (n=1)	Foreign body aspiration
Soft tissue shadow occluding the laryngeal air column (n=4)	Presence of mass in the larynx (n=4)	Laryngeal tumour
Narrowing of laryngeal air column (n=1)	Bulbous arytenoid with surrounding friable tissue (n=1)	Laryngeal tumour
Soft tissue shadow at the level of C5, C6 obliterating the laryngeal air column (n=1)	Oedematous arytenoid with fixation of vocal cords on both sides along with an ulcerating mass (n=1)	Laryngeal tumour with upper airway obstruction
Widening of prevertebral space with patchy lucency. Loss of cervical lordosis(n=2)	A bulge on the posterior pharyngeal wall and a nick yielding frank pus (n=2)	Retropharyngeal abscess
Deviation of trachea to the right (n=1)	Failed laryngoscopy	Thyroid tumour
Multiple rounded oval-shaped size opacities of metallic density (pellets) (n=1)	Nil	Gunshot to neck

*Two patients; foreign body ingested was a coin in one patient and peg-pin in the second patient

Table 3. Composition of foreign body ingested/inhaled

Foreign body	Number	%
Dentures	3	50.0
Coin	1	16.7
Peg-pin	1	16.7
Metallic fragment	1	16.7
Total	6	100.0

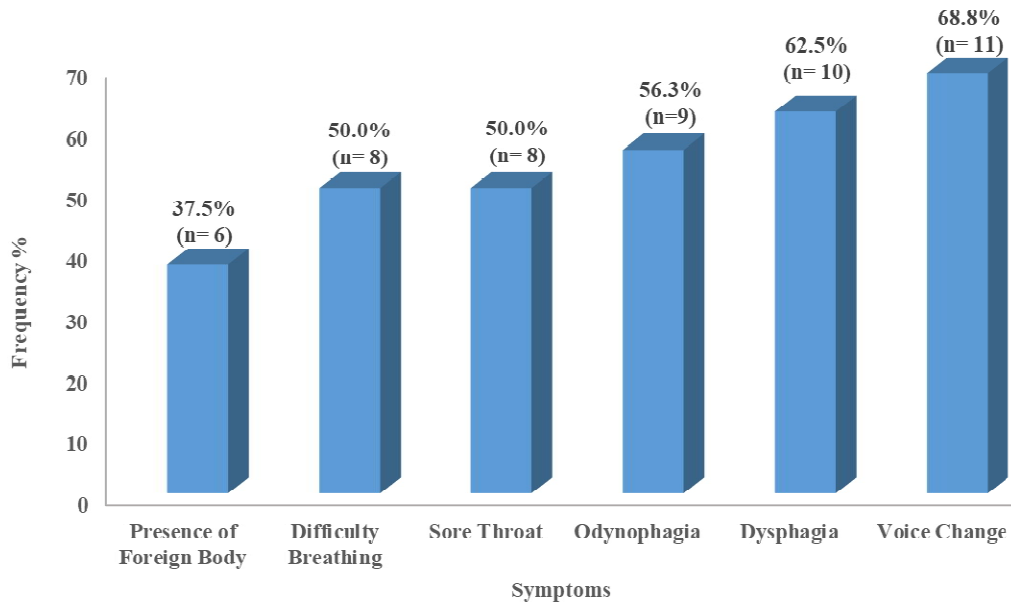


Fig. 1. Distribution of patients' complaints

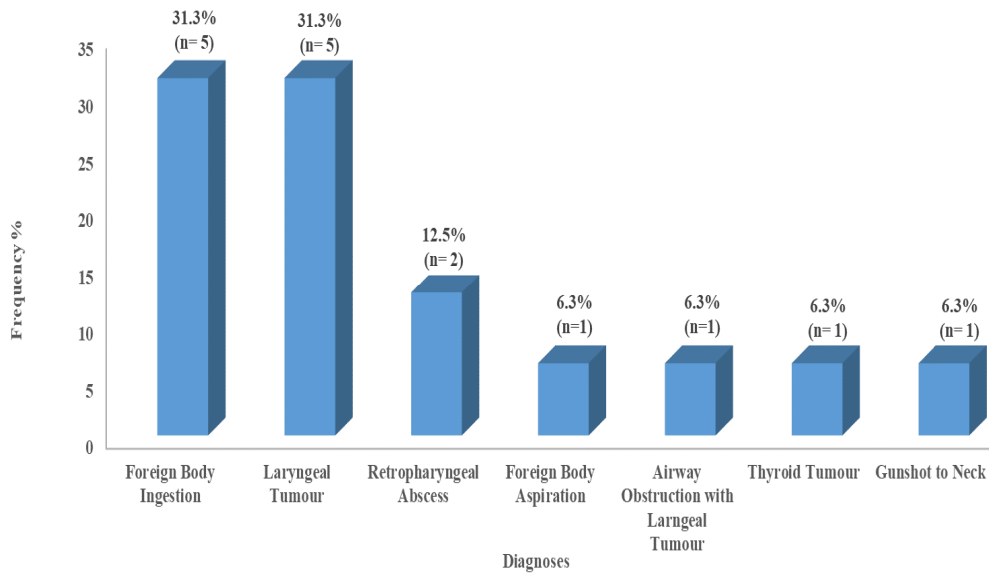


Fig. 2. Distribution of patients' diagnosis

$$\begin{aligned}
 \text{Sensitivity} &= \frac{\text{TruePositive}}{\text{TruePositive} + \text{FalseNegative}} \times 100 \\
 &= \frac{6}{6+0} = 100.0\%
 \end{aligned}$$

$$\text{Specificity} = \frac{\text{TrueNegative}}{\text{TrueNegative+FalsePositive}} \times 100$$

$$= \frac{7}{7+0} = 100.0\%$$

$$\text{Positive Predictive Value (PPV)} = \frac{\text{True Positive}}{\text{TruePositive+False Positive}} \times 100$$

$$= \frac{6}{6+0} = 100.0\%$$

$$\text{Negative Predictive Value (NPV)} = \frac{\text{True Negative}}{\text{TrueNegative+False Negative}} \times 100$$

$$= \frac{7}{7+0} = 100.0\%$$

$$\text{Sensitivity} = \frac{\text{TruePositive}}{\text{TruePositive+FalseNegative}} \times 100$$

$$= \frac{4}{4+1} = 80.0\%$$

$$\text{Specificity} = \frac{\text{TrueNegative}}{\text{TrueNegative+FalsePositive}} \times 100$$

$$= \frac{8}{8+0} = 100.0\%$$

$$\text{Positive Predictive Value (PPV)} = \frac{\text{True Positive}}{\text{TruePositive+False Positive}} \times 100$$

$$= \frac{4}{4+0} = 100.0\%$$

$$\text{Negative Predictive Value (NPV)} = \frac{\text{True Negative}}{\text{TrueNegative+False Negative}} \times 100$$

$$= \frac{8}{8+1} = 88.9\%$$

Table 4. Comparison of soft tissue neck radiograph and Oesophagoscopy/Laryngoscopy for the presence of foreign body among patients

		Oesophagoscopy/Laryngoscopy		
		Foreign body	No foreign body	Total
Soft tissue Neck radiograph	Foreign body	6 True positive	0 False-positive	6
	No foreign body	0 False-negative	7 True negative	7
	Total	6	7	13

Kappa Agreement= 1.00 (95% Confidence Interval: 1.00-1.00)

Table 5. Comparison of soft tissue neck radiograph and direct laryngoscopy for laryngeal tumour

		Direct Laryngoscopy		
		Laryngeal tumour	No laryngeal tumour	Total
Soft tissue neck radiograph	Laryngeal tumour	4 True positive	0 False-positive	4
	No laryngeal tumour	1** False-negative	8 True negative	9
	Total	5	8	13

Kappa Agreement= 0.83 (95% Confidence Interval: 0.52-1.00)

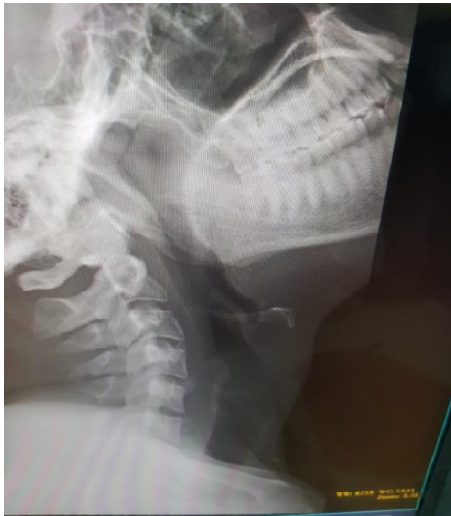

Fig. 3. Showing normal radiograph of the lateral neck

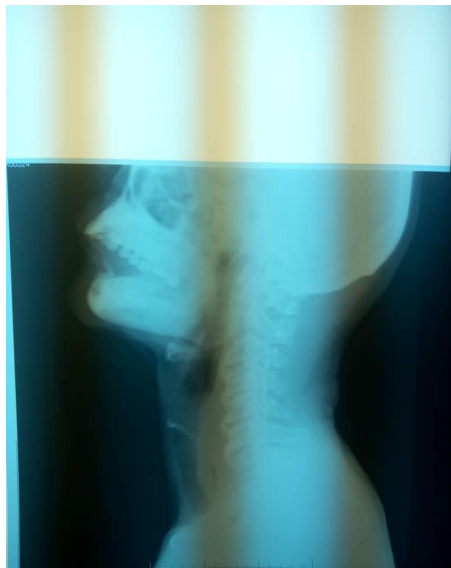

Fig. 4. An adult male with swallowed denture

Note: The loss of normal cervical lordosis, the widened prevertebral space with entrapped air around cervical spine 6 and T1. The denture is radiolucent, therefore not seen. However the air entrapment is an indication of the location

4. DISCUSSION

A total number of of16 patients were studied and children constituted only 31.25%. Majority of the patients were males 87.5%. This finding of a few children is in contrast to other works where the majority were of the paediatric age group [1,22]. However, these studies were on foreign body ingestions and it is known that foreign body ingestion/inhalation occurs more in children and edentulous adults and those with psychiatric problems [23]. Male preponderance was recorded agreeing with other researchers [6,22] but the ratio was higher; 7:1 compared to 1.6:1 in these other studies [6,22].

The commonest complaint of voice change followed by dysphagia is expected since the commonest aerodigestive emergency encountered in the study was foreign body ingestion/inhalation and laryngeal tumour.

The x-ray lateral soft tissue neck was able to make a positive diagnosis in n=14(87.5%) which was also confirmed by the operative findings. This result is close to the findings of Malik et al where the diagnosis was positive in 240 patients and operative findings confirmed the diagnosis in 220 of the cases [22]. while Saki, et al. had 98% correct diagnosis confirmed also at the surgery [24]. Karnwal, et al. found lateral soft tissue neck X-ray useful in the management of 51.6% of their patients [19].

The upper aerodigestive emergency in the present study was foreign body ingestion (mainly non-radiopaque) and laryngeal tumour. Therefore the diagnosis of lateral soft tissue neck radiograph was based more on the presence of soft signs such as prevertebral space widening, air entrapment and loss of normal cervical lordosis as well as soft tissue shadows. In another study, soft signs were found in 38.7% of the patients studied [19]. Diagnosis based on presence of radio-opacity was seen in only 3 cases similar to another work where only 10% of the foreign body was radio-opaque [25]. In

contrast, however, another study on children found the most ingested foreign body to be radiopaque [26].

While denture was the commonest foreign body seen in the adults, the recorded coin, metallic peg and metal fragment were all seen in the children. In contrast in the study by Adhikari et al, meat bone was the most object implicated in adults while the coin was the commonest seen in children, dentures were only seen in 2.4% of their patients [6]. Most of the foreign bodies seen in the present study were mainly located at or just below the cricopharyngeal constriction. The patient with the aspirated foreign body had it located at around the laryngeal inlet with obvious airway obstruction. In the present study aspirated foreign body was few, possibly because this tends to be commoner in children and the population here is more of adults.

Majority of the patients that presented with aerodigestive emergency had a laryngeal tumour which showed mainly as soft tissue shadow obliterating the laryngeal air column on the X-ray and was confirmed on endoscopy. These patients presented with varying degrees of upper airway obstruction with a good number requiring tracheostomy as part of the initial treatment. They, however, had other modalities of imaging done after the endoscopy to determine the extent of their disease and planning of definitive management. The patients with a retropharyngeal abscess which is a deep neck space abscess that occurs more commonly in children less than 6 years, [27] were diagnosed accurately from the lateral neck x-ray based on widening of the prevertebral space with patchy lucencies and were confirmed at surgery. This finding is similar to a study that found it's specificity to be 100% and sensitivity 80% [28].

In this study, lateral neck x-ray was found to have a specificity of 100% as a tool for diagnosis in both foreign body ingestion/inhalation and laryngeal tumour, however, the sensitivity is better in foreign body detection 100%, than laryngeal tumour; 80% as an upper aerodigestive emergency. The positive predictive value was found to be 100% while the negative was 88.9% for laryngeal tumour but 100% for both positive and negative predictions for foreign body. This investigative tool has its accuracy depends on the skills and experience of whosoever is interpreting it. Therefore there is a wide range of findings when compared to that of different

researchers on the usefulness of this tool. While WU et al had the sensitivity of 57.4% and specificity of 76.1% with a detection rate of 73% for foreign bodies in the hypopharynx and cervical oesophagus [29], Saki, et al. had sensitivity 100% and specificity 84.2% and a rate of 98% of accuracy. [23] Malik, et al. on the other hand, had a positive predictive value of 95.6% and negative of 66.7%, the sensitivity was 91.7% and specificity of 80%. The accuracy was determined to be 89.7%. [22] The work by Adhikari et al, however, showed that 84.4% had positive findings but the sensitivity was better for coin ingestion with 85% while for meat bones it was 43.7% [6]. The overall detection rate of the lateral soft tissue neck, especially for foreign body ingestion, is found to be 70-80%. In the present study, we found it to be higher. However, from the above, most researchers seem to have found this tool helpful in making this diagnosis [6,11,19]. The findings in this study agrees with some researcher that lateral soft tissue neck X-ray is more accurate in foreign bodies lodged in the hypopharynx and cervical oesophagus [25,29]. Therefore a lateral soft tissue neck radiograph is a useful adjunct in diagnosing and managing patients with upper aerodigestive disorders.

5. CONCLUSION

In this study lateral soft tissue neck x-ray was found to be a good and useful tool in the diagnosis of a good number of upper aerodigestive emergencies such as foreign body ingestion/inhalation and patients with upper airway obstruction caused by laryngeal tumours and some infective conditions such as a retropharyngeal abscess. The radiologists, as well as the otorhinolaryngologist, should be aware of the normal anatomy and major foreign body mimics in the lateral soft tissue neck radiographs to maximize the usefulness of this tool. It is readily available, cheap and can be the very first line of and sometimes the only investigation required in these patients before definitive treatment. In such instances, clinical assessment when combined with the plain radiograph of the lateral neck may suffice in making the diagnosis in upper aerodigestive emergencies.

6. LIMITATIONS

Owing to the small sample size the conclusions will have to be cautiously implied.

CONSENT AND ETHICAL APPROVAL

Informed consent was obtained from each of the patients in the study group. Information sought from the patients included biodata, clinical presentations, X-ray and operative findings these were entered into a Proforma. Permission was sought and obtained from the ethical committee for the study.

COMPETING INTERESTS

Authors have declared that no competing interests exist.

REFERENCES

1. Gilyoma JM, Chalya PL. Endoscopic procedures for removal of foreign bodies of the aerodigestive tract: The Bugendo medical centre experience. *BMC Ear Nose Throat Discord.* 2011;11:2.
2. Ibekwe MU, Onotai LO, Otaigbe B. Foreign body in the ear, nose and throat in children: A five year review in Niger Delta. *Afr J Paediatr Surg.* 2012;9(3):3-7.
3. Offer GJ, Nanan D, Marshall JN. Thermal injury after micro wave heating of food. *J Accid Emerg Med.* 1995;12:216-217.
4. Onotai LO, Ibekwe MU. Pattern of cut throat injuries in the University of Port Harcourt Teaching Hospital. *Niger J Med.* 2010;19(3):264-266.
5. Herdman RC, Saeed SR, Hinton EA. The lateral soft neck x-ray in accident & emergency medicine. *Arch Emerg Med.* 1992;9(2):149-156.
6. Adhikari P, Bhatta R, Polcharel R, Baskota DK, Sinha BK. Role of plain X-ray soft tissue neck lateral view in the diagnosis of cervical oesophageal foreign bodies. *Int J Otorhinolaryngol.* 2009;8:2.
7. Rahman AA. Removal of foreign bodies upper end oesophagus. *J Postgrad Med Inst.* 2004;18:681-684.
8. Wong K, Fang C, Tam Paul KH. Selective upper endoscopy of foreign bodies ingestion in children: An evaluation of management protocol after 282 cases. *J Ped Surg.* 2006;41:2016-2018.
9. Umihanic S, Brick F, Hodzic S. Foreign body in oesophagus: Experiences at ear-nose-throat clinic in Tuzla, 2003-2013. *Kulak Burun Bogaz Ihtis Derg.* 2015;25: 214-218.
10. Adhikari P, Peluschi S, Bianchini C, Ciorba A, Pastore A. Unusual foreign body in the upper cervical oesophagus: Case report. *Acta Otorhinolaryngol Ital.* 2007;27(1):38-40.
11. Walner DL, Ouanounou S, Donnelly LF, Cotton RT. Utility of radiographs in the evaluation of paediatric upper airway obstruction. *Ann Otol Rhinol Laryngol.* 1999;108:378-383.
12. Shetty D, Gay D. The lateral neck radiograph for an impacted fish bone in the aerodigestive tract: going back to basics. *Journal of Biomedical Science and Engineering.* 2012;5(12):826-828.
13. Virk JS, Virk S, Pang J, Okhovat S, Lingam RK, Singh A. Analyzing lateral soft tissue neck radiographs. *Emerg Radio.* 2012;19(3):255-260.
14. Chung CH, Lau CK, Chow T. Swallowed foreign bodies in adults. *Hong Kong Practitioner.* 1991;13:1805-1811.
15. Siva AB, Muntz HR, Clary R. Utility of conventional radiograph in the diagnosis and management of pediatric airway foreign bodies. *Ann Otol Rhinol Laryngol.* 1998;107:834-838.
16. Denny W, Ahmad N, Dillard B, Nowicki MJ. Children will eat the strangest things: A 10-year retrospective analysis of foreign body and caustic ingestions from a single academic center. *Pediatr Emerg Care.* 2012;28(8):731-734.
17. Kim SY, Park B, Kong IG, Choi HG. Analysis of ingested foreign bodies according to age type and location: A retrospective observational study. *Clin Otolaryngol.* 2016;41(6):640-645.
18. Castan SA, Dinu LE, Artigas JM, Larrosa R, Navarro Y, Angulo E. Foreign bodies on lateral neck radiographs in adults: Imaging, findings and common pitfalls. *Radiographics.* 2017;37(1):323-345.
19. Karnwal A, Ho EC, Hall A, Molony N. Lateral soft tissue neck x-ray: Are they useful in management of upper aerodigestive tract foreign body. *J Laryngol Otol.* 2008;122(8):845-847.
20. Kirkwood BR, Sterne JAC. Calculation of required sample size. *Essential medical statistics.* 2nd edition. United Kingdom: Blackwell Science. 2003;420-421.
21. Kifi AM, Mohammed GM, Abubakar TS, Labaran AS, Samdi MT, Fufore MB. Clinical profile and management of aerodigestive foreign bodies in the North western Nigeria. *Sudan Medical Monitor.* 2014;9(1):39-43.

22. Malik SA, Qureshi IA, Muhammad R. Diagnostic accuracy of plain x-ray lateral neck in the diagnosis of cervical oesophageal foreign bodies keeping oesophagoscopy as gold standard. J Ayub Med Abbottabad. 2018;30(3):386-388.
23. T-Ping C, Nunes CA, Guimaraes GR, Vieira JP, Weeks LL, Borges T. Accidental ingestion of coins by children: Management at the ENT department of Joao xxiii Hospital Vraz J Otorhinolaryngol. 2006;72(4):470-474.
24. Saki N, Nikakhlagh S, Tahmasebi M. Diagnostic accuracy of conventional radiography for oesophageal foreign body in adults. Iran J Radiol. 2008;6(1):199-204.
25. Ruiz FE. Airway foreign bodies in children In: Baswo Ds, ed. up to date. Waltham, Mass: Upto Date; 2013.
26. Pinto A, Lanza C, Pinto F, Grassi R, Romano L, Brunese L. Role of plain radiography in the assessment of ingested foreign bodies in the paediatric patients. Semin Ultrasound CT MR. 2015; 36(1):21-27.
27. Uzomefuna V, Glynn F, Mackle T, Russell J. Atypical locations of retropharyngeal abscess: beware of the normal lateral soft neck x-ray. Int J Pediatr Otorhinolaryngol.2010;74(12):1445-1448.
28. Boucher C, Dorion D, Fisch C. Retropharyngeal abscesses: A clinical and radiologic correlation. J Otolaryngol. 1999; 28(3):134-137.
29. Wu IS, Ho TL, Chang CC, Lee HS, Chen MK. Value of lateral neck radiography for ingested foreign bodies using the likelihood ratio. J Otolaryngol Head Neck Surg. 2008; 37(2):292-296.

© 2019 Uju and Edirin; This is an Open Access article distributed under the terms of the Creative Commons Attribution License (<http://creativecommons.org/licenses/by/4.0>), which permits unrestricted use, distribution, and reproduction in any medium, provided the original work is properly cited.

Peer-review history:
The peer review history for this paper can be accessed here:
<http://www.sdiarticle4.com/review-history/52355>