

Wrist Spanning versus Non Spanning Technique of External Fixation in Distal Radius Fractures: A Randomised Clinical Trial

SAIKAT SARKAR¹, SUBHANKAR MUKHERJEE², KAUSHIK MANDAL³, PRASUN MANDAL⁴

ABSTRACT

Introduction: External fixation is one of the treatment options for unstable Distal Radius Fractures (DRF). Extra-articular variety of DRF can be managed by both wrist joint spanning and non spanning types of external fixators. Literature comparing the outcome of these two techniques is scarce.

Aim: To compare and evaluate the results of treatment of DRF with wrist spanning and non spanning techniques.

Materials and Methods: A randomised clinical trial study was carried out at Medical College and Hospital, Kolkata, India from November 2017 to January 2019. It included 30 patients, 15 had been treated by spanning and 15 by non spanning external fixators. They were evaluated during the immediate postoperative period, six weeks, nine weeks, and 12 weeks after surgery using digital roentgenography, Disability of Arm, Shoulder, and Hand (DASH) questionnaire, and Visual Analog Scale (VAS) for pain

and clinical assessment. A radiological assessment of volar tilt, radial height, and radial inclination was done and the data was normally distributed and analysed by unpaired t-test.

Results: The DASH score was better at 12 weeks in the non spanning group, with a mean of 21.89 in spanning vs 19.3 in the non spanning group (p-value 0.0412). At 12 weeks, the mean and p-value for the spanning and non spanning group: range of flexion (61.87 and 70.46), extension (66.13 and 71.13, p-value=0.0053), supination (73.2 and 74.9) and pronation (77.20 and 79.8). For spanning and non spanning groups, the volar tilt mean was 2.33 and 0.60 with a p-value of 0.0042 and the radial length mean was 1.27 and 0.33 with p-value 0.0013, in favour of the non spanning technique.

Conclusion: According to the present study, Non spanning external fixation is a better operative technique than spanning external fixation. Unstable DRFs can be treated better by a non spanning external fixator.

Keywords: Extra-articular, External fixator, Supination, Volar tilt

INTRODUCTION

The distal radius fractures represent approximately one-sixth of all fractures treated by orthopaedic surgeons. It has a bimodal age distribution, affecting youths under the age of 18 and elderly patients with osteoporotic bone [1]. These fractures should be assessed and treated timely to prevent angulations, shortening, and articular incongruity.

There are various options for the treatment of DRF, and they include closed reduction and casting, closed reduction and percutaneous pinning, external fixation, and open reduction with internal fixation [2]. The outcome of the treatment of DRF depends upon a good understanding of the classification of the same. Indications of surgery can be divided into four factors namely, patient factors, fracture stability, fracture reduction, and presence of associated factors [3]. Unstable DRF can be treated by external fixators which are of two types- bridging or wrist joint spanning and non bridging or non wrist joint spanning. External fixation has been shown to improve stability in elderly osteoporotic fractures. External fixation may yield adequate mobility and grip strength with favourable radiological outcomes [4]. Even though its use is declining because of a complication rate of up to 62%, it is still widely used in resource-poor settings, or in cases where the patient can't afford the cost of a better treatment modality [5,6]. The complications apart from osteomyelitis range from varied soft tissue issues like tendon injury, vascular compromise, nerve injury, complex regional pain syndrome, compartment syndrome etc., [7]. In the Indian population, there is a scarcity of literature comparing the relative effectiveness of two types of external fixation, [7,8]. Therefore, a randomised clinical trial study was carried out to compare the radiological and functional outcomes of both these techniques and the complications associated with both techniques.

MATERIALS AND METHODS

A randomised clinical trial study was carried out in Medical College and Hospital, Kolkata, India, from November 2017 to January 2019. Institutional Ethics Committee clearance was taken vide reference number MC/Kol/IEC/Non spon/471/12-2016.

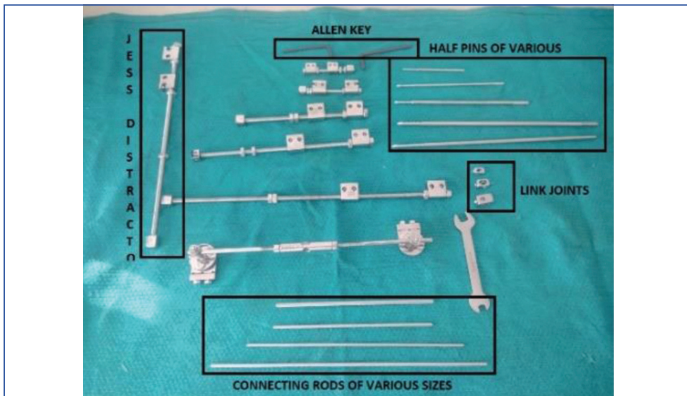
Inclusion and Exclusion criteria: The study involved patients aged 15-65 years with unstable distal end radius fractures. In skeletally immature patients with open physis, physal sparing fixation with a smooth Steinman pin was done. Those with intra-articular fracture; fracture with <1 cm intact volar cortex on the distal fragment, or previous malunited fractures were excluded. Those patients attending with a history of the two-week interval between injury to recognition of instability were exempted from the study. Those unable to perform the functional evaluation or having mental illness were also excluded.

Patients who presented to the outpatient department or emergency department with fractures of distal radius were screened and recruited according to inclusion and exclusion criteria. Before enrolment, all patients gave informed consent. The fractures were classified according to AO classification [6]. In the operating room, they were assigned to two separate treatment groups randomly. A computer generated randomisation list was used and the patient was divided into either group by sequentially opening sealed cards in the operating room. No further blinding was done.

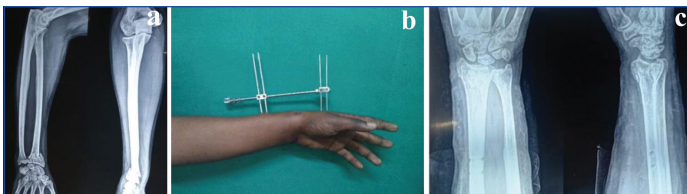
Study Procedure

The external fixator set used is shown in [Table/Fig-1]. For wrist spanning, Joshi's External Stabilisation System (JESS) was used [7]. The patient was given regional anaesthesia. Positioning was done, with the patient in a supine position and hand on the arm table with C Arm guidance. Two pins of 3.5 mm diameter were put in the radius, proximal to the fracture and longitudinally parallel to each other.

Similarly, 2 pins of 2.5 mm diameter were inserted in the second metacarpal longitudinally parallel to each other. Closed reduction of the fractures was done and the fixator was locked [Table/Fig-2].

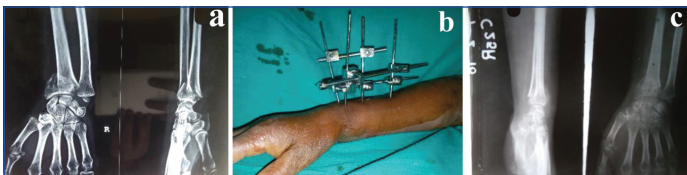

[Table/Fig-1]: External fixator set used.



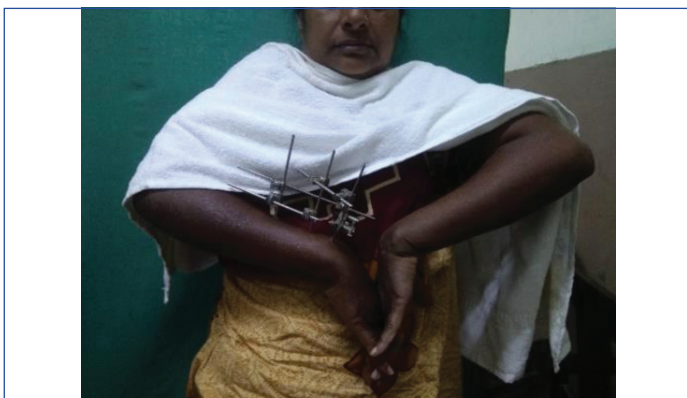[Table/Fig-2a-c]: Spanning fixator (Preoperative, Intraoperative and postoperative).

For non wrist joint spanning, mini external fixator was used with 3.5 mm and 2.5 mm half pins and stainless steel connecting rods and clamps (Link Joints) [Table/Fig-3]. Positioning was the same and C Arm guidance was used. Two longitudinally parallel pins were inserted in the radius proximal to the fracture. Two transversely parallel 2.5 mm pins were inserted in the distal fragment after dissecting the tendon of the Extensor Pollicis Longus (EPL). These pins were inserted parallel to the articular surface. The distal pins were used to manipulate the fracture and achieve reduction and then the external fixator was locked using connecting rods and clamps [9].



[Table/Fig-3a-c]: Non spanning fixator (Preoperative, Intraoperative and postoperative).

Postoperatively, broad-spectrum antibiotics were given and were advised proper pin tract care and active finger movement exercise, wrist movement exercise (non spanning group), elbow and shoulder movement exercises. The external fixators were maintained for a period of 6 weeks for both groups after which it was removed. Then they were advised to active physiotherapy of fingers, wrist, elbow, and shoulder joints [Table/Fig-4].



[Table/Fig-4]: Active range of motion at wrist joint in non spanning group.

Outcome measures: On admission demographic data of each patient was recorded and the fracture was classified according to the AO Muller classification [6,7]. Patients were followed up at 6 weeks, 9 weeks, and 12 weeks. DASH scores were calculated from DASH questionnaires completed by the patients [10]. The pain was assessed by the patient with the help of a VAS and was graded from 0 to 10 [11]. Active range flexion and extension at the wrist joint and supination and pronation of the radio-ulnar joint were measured in degrees. On each follow-up visit, DASH scores were calculated, pain score by VAS was determined and range of motion was measured [Table/Fig-5]. Radiological assessments were carried out at six weeks (after removal of the external fixator) and 12 weeks. Radiographs (postero-anterior and lateral view) were obtained on each visit and measurements were taken.



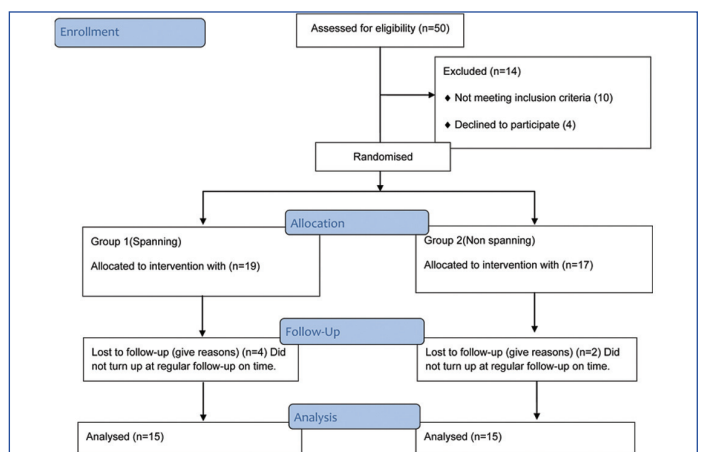
[Table/Fig-5]: Functional assessment by holding a bottle of water.

STATISTICAL ANALYSIS

Graph Pad Prism version 5 (San Diego, California: GraphPad Software Inc., 2007) was used for statistical analysis. The data were normally distributed and therefore analysed by unpaired t-test. A p-value less than 0.05 were considered significant.

RESULTS

Out of the 36 patients included following the inclusion and exclusion criteria, 30 completed the follow-up period of 12 weeks and their data were taken for analysis [Table/Fig-6]. Of them, 15 belonged to the non spanning group. The mean age of the patients was 46.63 ± 10.06 years (ranging from 27 years to 66 years). Eleven (36.67%) out of 30 were males. The spanning group consisted of 5 males and 10 females while the non spanning group had 6 male and 9 female patients. The mode of injury was mostly falling from standing height in 17 (56.67%) cases, three had a sports injury and the rest had a history of fall on an outstretched hand. Six patients had high-energy trauma which lead to severely comminuted fractures. 17 (56.67%) had a fracture of AO type 23-A2.2. AO type 23-A2.3 type of fracture was noted in 9 (30%). Remaining 4 (13.33%) had AO type 23-A2.1.



[Table/Fig-6]: CONSORT 2010 flow diagram.

DASH scores were similar at 6 weeks and 9 weeks, but significantly less in the non spanning group at 12 weeks. The pain was less in the non spanning group in all three follow-up visits but the difference was not significant [Table/Fig-7].

Score (Week)	Spanning Group (n=15)	Non spanning group (n=15)	p-value
DASH Score			
6	67.33 (9.82)	68.56 (9)	0.7322
9	48.56 (5.97)	48.89 (5.34)	0.8733
12	21.89 (3.38)	19.3 (3.15)	0.0412*
Pain (VAS)			
6	7.13 (1.30)	7 (1.25)	0.7772
9	4.26 (1.43)	3.86 (1.18)	0.4131
12	1.93 (0.79)	1.73 (0.70)	0.4729

[Table/Fig-7]: Evaluation of DASH score and VAS in spanning and non spanning groups. Results are expressed as mean (SD); p-value obtained by unpaired t-test; *indicates significance

[Table/Fig-8] indicates that the range of motion of all types of movement in the wrist joint was better in the non spanning group in all three follow-up visits.

Motion (Week)	Spanning Group (n=15)	Non Spanning Group (n=15)	p-value
Flexion			
6 wk	22.53 (4.5)	31.73 (4.74)	<0.0001
9 wk	38.3 (5.02)	47.6 (4.85)	0.3202
12 wk	61.87 (5.26)	70.46 (4.82)	0.5414
Extension			
6 wk	13 (3.02)	22.06 (2.89)	<0.0001
9 wk	36.86 (4.65)	40.53 (3.66)	0.0235*
12 wk	66.13 (4.92)	71.13 (4.08)	0.0053*
Pronation			
6 wk	40.4 (3.11)	46.2 (4.42)	<0.0001
9 wk	59.06 (2.31)	63.46 (4.13)	0.0012*
12 wk	77.20 (3.01)	79.8 (4.76)	0.0849
Supination			
6 wk	33.2 (4.41)	40.33 (4.01)	0.0003*
9 wk	53.2 (3.40)	57.6 (5.36)	0.0121*
12 wk	73.2 (3.51)	74.93 (4.13)	0.2258

[Table/Fig-8]: Comparison of range of motion in spanning and non spanning group. Results are expressed as mean (SD); p-value obtained by unpaired t-test; *indicates significance

The loss of volar tilt in the bridging group between 6th and 12th week was significantly more compared to the non bridging group (2.33 vs 0.60). Loss of radial height was also significantly less in the non bridging group (1.27 vs 0.33). Even though the loss of radial inclination was more in spanning group, the difference did not reach statistical significance [Table/Fig-9].

Pin tract infection was reported in a total of seven cases; three in the spanning group and four in the non spanning group. In five cases there was pin tract infection at the distal pin of the radial shaft. In the rest two cases, there was infection at the proximal metacarpal pin. There was no rupture of EPL reported in the non spanning group. None of the patients developed complex regional pain syndrome. There was no other major or minor complication reported.

DISCUSSION

Management of DRF has undergone an evolution over the years. The same mode of management is not applicable for different fracture patterns of distal radius as the anatomical and mechanical forces acting are different [9]. Cast immobilisation can prevent surgery and its associated complications but it leads to inadequate fixation and loosening of reduction in patients who do not come for

Radiological parameters (Week)	Spanning Group (n=15)	Non Spanning Group (n=15)	p-value
Volar Tilt (degree)			
6	9.67 (1.87)	9.93 (1.16)	0.6436
12	7.33 (1.98)	9.33 (1.39)	0.0035*
Loss of volar tilt	2.33 (1.50)	0.60 (0.91)	0.0042*
Radial Height (mm)			
6	8.73 (2.01)	9.53 (1.24)	0.2018
12	7.46 (1.59)	9.20 (1.32)	0.0031*
Loss of radial height	1.27 (0.88)	0.33 (0.49)	0.0013*
Radial Inclination (degree)			
6	17.93 (4.49)	20.80 (1.69)	0.0285*
12	16.6 (4.20)	19.60 (2.16)	0.0205*
Loss of radial inclination	1.33 (1.68)	1.20 (1.37)	0.81

[Table/Fig-9]: Evaluation of the radiological parameters. Results are expressed as mean (SD); p-value obtained by unpaired t-test; *indicates significance

periodic radiological evaluation [12]. External fixation is considered a better treatment method compared to conservative management [4]. Bridging external fixation employs the principle of ligamentotaxis to maintain reduction, while the non bridging technique employs direct fixation of the fracture. In the case of severely comminuted fractures, better restoration of the near-normal anatomy of the distal radius can be done by external fixation [13]. Open Reduction and Internal Fixation (ORIF) has gained popularity recently, and is considered the treatment of choice for DRF with intra-articular extension [14,15]. It has the advantage of directly manipulating and fixing the fractures. Compared with external fixation, ORIF techniques have shown early rehabilitation benefits [16]. However, a meta-analysis performed by Margaliot Z et al., concluded that there was no significant difference between ORIF and external fixation for DRF [17]. Another modification of external fixation that allowed movement at the wrist joint showed preservation of reduction and early return of function [18].

This study demonstrated a favourable DASH score at 12 weeks and significantly better joint mobility in all the follow-up visits in the non spanning group. Atroschi I et al., in their study though did not find a significant scoring in favour of the non bridging technique except at 10 weeks [19]. They did not find any significant difference in the symptoms and disability outcomes in both the techniques and were also of the opinion that a larger study sample might show a favourable outcome favouring the non bridging technique. McQueen MM has demonstrated in her randomised study that a non spanning external fixator was superior to spanning external fixation with percutaneous pinning in patients who had lost acceptable reduction of their DRF [20]. This study is in agreement with this finding, barring comment on percutaneous pinning as it was not required in any of our cases. In another study, McQueen MM et al., stated that the anatomic results were acceptable, but non satisfactory in respect of functional outcomes like grip strength and ease of doing activities of daily living [21,22].

The range of motion was better preserved in the non spanning group and thereby the functional result was also satisfactory. Uchimura C et al., in their study concluded that non bridging patients showed a better outcome [23]. Hayes AJ et al., in their study recommended non bridging external fixation when there is space for pin placement in distal fragment as the chances of complications and malunion are less [24]. In the present study, non spanning technique gives better radiological and functional outcomes. Though there are other studies that give a differing opinion regarding the preferred technique suggesting equivocal results with both techniques the reason probably being small sample size. Gu WL et al., in a study suggested that the chances of pin track infections and nerve injury are much less in the bridging technique with no functional result

difference hence preferred over non bridging one [25]. Aita MA et al., in their study on elderly patients with polytrauma found both techniques gave similar grip strengths and comparable return to activities of daily living [26]. Similarly, Krishnan J et al., found no significant statistical difference in the end result, be it radiological or functional [27]. The use of external fixator is gradually declining because of multiple reasons like high rates of complications, increased comorbidity associated with external implants, improved implants for ORIF, and patient and surgeon preference [28]. Still, this is the preferred mode of treatment in rural areas with resource-limited settings.

Limitation(s)

The lack of a larger sample size and a longer period of follow-up were the limitations of the study.

CONCLUSION(S)

Non spanning external fixation is a better operative technique than spanning external fixation in the treatment of unstable distal radius extra-articular fracture being inexpensive, less technically demanding, with acceptable fracture union, better functional outcome, and with minimal postoperative complication.

There is no conflict of interest to declare for this study.

Acknowledgement

We are thankful to Prof (Dr) Michael Hira, Professor, Department of Orthopaedics, Medical College, Kolkata for his help during the study.

REFERENCES

- [1] Singer BR, McLauchlan GJ, Robinson CM, Christie J. Epidemiology of fractures in 15,000 adults: the influence of age and gender. *J Bone Joint Surg Br.* 1998;80(2):243-48.
- [2] Leung F, Tu YK, Chew WY, Chow SP. Comparison of external and percutaneous pin fixation with plate fixation for intra-articular distal radial fractures. A randomised study. *J Bone Joint Surg Am.* 2008;90(1):16-22.
- [3] Ilyas AM, Jupiter JB. Distal radius fractures--classification of treatment and indications for surgery. *Orthop Clin North Am.* 2007;38(2):167-73.
- [4] Moroni A, Vannini F, Faldini C, Pegreff F, Giannini S. Cast vs external fixation: a comparative study in elderly osteoporotic distal radial fracture patients. *Scand J Surg.* 2004;93(1):64-67.
- [5] Bohra AK, Vijayvergiya SC, Malav R, Jhanwar P. A prospective comparative study of operative treatment of distal radius fracture by using locking and non locking volar T-plate. *JPBMS.* 2012;20(14):05-07.
- [6] Azar FM, Beaty JH, Canale ST. *Campbell's Operative Orthopaedics*, 14th Edition. Philadelphia: Elsevier; 2020.
- [7] Chilakamary VK, Lakkireddy M, Koppolu KK, Rapur S. Osteosynthesis in distal radius fractures with conventional bridging external fixator; tips and tricks for getting them right. *J Clin Diagn Res.* 2016;10(1):RC05-RC08.
- [8] Ranjan R, Yadav S, Agarwal A, Das R, Sakale H, Kar B. External fixator for distal radius fractures. *J Orthop Dis traumatol.* 2020;3(2):49.
- [9] Wright TW, Horodyski M, Smith DW. Functional outcome of unstable distal radius fractures: ORIF with a volar fixed-angle tine plate versus external fixation. *J Hand Surg.* 2005;30A:289-99.
- [10] Arora R, Gabl M, Erhart S, Schmidle G, Dallapozza C, Lutz M. Aspects of current management of distal radius fractures in the elderly individuals. *Geriatr Orthop Surg Rehabil.* 2011;2(5-6):187-94.
- [11] Sung YT, Wu JS. The visual analogue scale for rating, ranking and paired-comparison (VAS-RRP): a new technique for psychological measurement. *Behavior Research Methods.* 2018;50(4):1694-715.
- [12] Leung KS, Shen WY, Tsang HK, Chiu KH, Leung PC, Hung LK. An effective treatment of comminuted fractures of the distal radius. *J Hand Surg Am.* 1990;15:11-17.
- [13] Schmalholz A. External skeletal fixation versus cement fixation in the treatment of redislocated Colles' fracture. *Clin Orthop Relat Res.* 1990;254:236-41.
- [14] Edwards GS Jr. Intra-articular fractures of the distal part of the radius treated with the small AO external fixator. *J Bone Joint Surg Am.* 1991;73:1241-50.
- [15] Jupiter JB. Complex articular fracture of the distal radius classification and management. *J Am Acad Orthop Surg.* 1997;5:119-29.
- [16] Dicipingaitis P, Wolinsky P, Hiebert R, Egol K, Koval K, Tejwani N. Can external fixation maintain reduction after distal radius fractures? *J Trauma.* 2004;57:845-50.
- [17] Margaliot Z, Haase SC, Kotsis SV, Kim HM, Chung KC. A meta-analysis of outcomes of external fixation versus plate osteosynthesis for unstable distal radius fractures. *J Hand Surg Am.* 2005;30:1185-99.
- [18] Clyburn TA. Dynamic external fixation for comminuted intra-articular fractures of the distal end of the radius. *J Bone Joint Surg Am.* 1987;69:248-54.
- [19] Atroshi I, Brogren E, Larsson GU, Kloov J, Hofer M, Berggren AM. Wrist-bridging versus non bridging external fixation for displaced distal radius fractures: a randomised assessor-blind clinical trial of 38 patients followed for 1 year. *Acta Orthop.* 2006;77:445-53.
- [20] McQueen MM. Redisplaced unstable fractures of the distal radius. A randomised, prospective study of bridging versus non bridging external fixation. *J Bone Joint Surg Br.* 1998;80:665-69.
- [21] McQueen MM, Michie M, Court-Brown CM. Hand and wrist function after external fixation of unstable distal radial fractures. *Clin Orthop Relat Res.* 1992;285:200-04.
- [22] Paksima N, Panchal A, Posner MA, Green SM, Mehlman CT, Heibert R. A meta-analysis of the literature on distal radius fractures: review of 615 articles. *Bull Hosp Jt Dis.* 2004;62(1-2):40-46.
- [23] Uchikura C, Hirano J, Kudo F, Satomi K, Ohno T. Comparative study of non bridging and bridging external fixators for unstable distal radius fractures. *Journal of Orthopaedic Science.* 2004;9:560-65.
- [24] Hayes AJ, Duffy PJ, McQueen MM. Bridging and non bridging external fixation in the treatment of unstable fractures of the distal radius- a retrospective study of 588 patients. *Acta Orthopaedic.* 2008;79(4):540-47.
- [25] Gu WL, Wang J, Li DQ, Gong MZ, Chen P, Li ZY, et al. Bridging external fixation versus non bridging external fixation for unstable distal radius fractures: A systematic review and meta analysis. *Journal of Orthopaedic Science.* 2016;21(1):24-31.
- [26] Aita MA, Rodrigues FL, Alves KHCR, Oliveira RK, Ruggiero GM, Rodrigues LMR. Bridging versus non bridging dynamic external fixation of unstable distal radius fractures in the elderly with polytrauma. A randomised study. *Journal of Wrist Surgery.* 201;8(5):408-15.
- [27] Krishnan J, Wigg AER, Walker RW, Slavotinek J. Intra articular fractures of the distal radius: A prospective randomised controlled trial comparing static bridging and dynamic non bridging external. *Journal of Hand Surgery.* 2003;28(5):417-21.
- [28] Azad A, Kang HP, Alluri RK, Vakshori V, Kay HF, Ghiassi A. Epidemiological and treatment trends in distal radius fractures across multiple age groups. *J Rist Surg.* 2019;8(4):305-11.

PARTICULARS OF CONTRIBUTORS:

1. Consultant Orthopaedic Surgeon, Department of Orthopaedics, Monorama Hospitex Pvt. Ltd., Ranaghat, West Bengal, India.
2. Associate Professor, Department of Orthopaedics, KPC Medical College, Kolkata, West Bengal, India.
3. RMO cum Clinical Tutor, Department of Orthopaedics, Medical College, Kolkata, West Bengal, India.
4. Associate Professor, Department of Orthopaedics, Sarat Chandra Chattopadhyay Government Medical College, Uluberia, West Bengal, India.

NAME, ADDRESS, E-MAIL ID OF THE CORRESPONDING AUTHOR:

Prasun Mandal,
B/H1/3/5 Lakeview Housing Complex Ichapur Dumurjala-711104,
Howrah, West Bengal, India.
E-mail: prasunortho81@gmail.com

PLAGIARISM CHECKING METHODS: [Jain H et al.]

- Plagiarism X-checker: Sep 17, 2022
- Manual Googling: Nov 22, 2022
- iThenticate Software: Dec 10, 2022 (7%)

ETYMOLOGY: Author Origin

AUTHOR DECLARATION:

- Financial or Other Competing Interests: None
- Was Ethics Committee Approval obtained for this study? Yes
- Was informed consent obtained from the subjects involved in the study? Yes
- For any images presented appropriate consent has been obtained from the subjects. Yes

Date of Submission: **Sep 09, 2022**

Date of Peer Review: **Oct 15, 2022**

Date of Acceptance: **Dec 15, 2022**

Date of Publishing: **Apr 01, 2023**